

Nasal valve stabilization

Nasal valve collapse is a challenging, but common, source of nasal obstruction.

Nasal valve stabilization is a new technique that draws on advantages of the nasal valve suspension techniques but minimizes the drawbacks associated with the suspension techniques.

Nasal valve compromise is a distinct cause of symptomatic nasal airway restriction, but it often remains a challenge to treat effectively [1].

1. Rhee JS, Weaver EM, Park SS, et al: Clinical consensus statement: Diagnosis and management of nasal valve compromise. Otolaryngol Head Neck Surg 143:48-59, 2010

# The internal nasal valve (“nasal valve”)

Is the triangular area of the nasal airway bounded by:

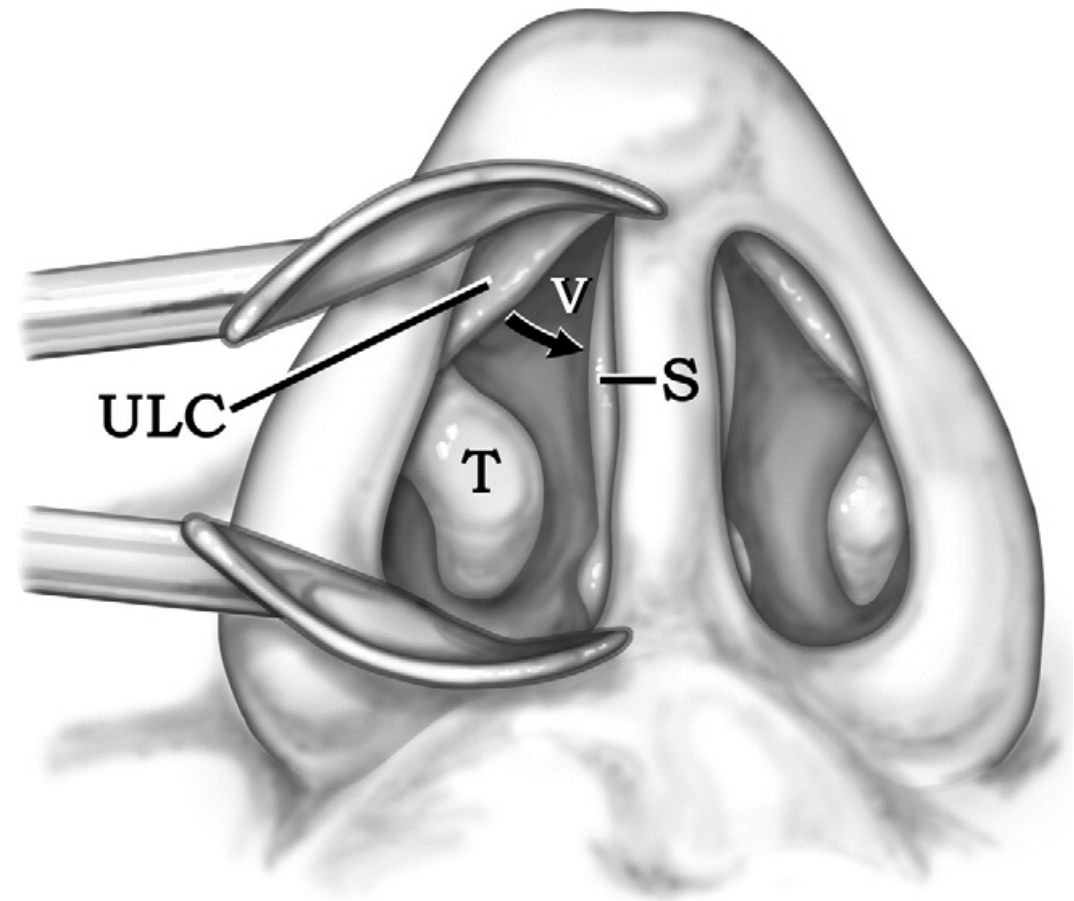
- septum medially,
- the caudal part of the upper lateral cartilage dorsolaterally,
- and the head of the inferior turbinate inferiorly

# Nasal valve anatomy (internal).

Speculum examination of the:

- right internal nasal valve (V),
- the space bounded by the caudal aspect of the upper lateral cartilage (ULC),
- the anterior part of the inferior turbinate (T),
- and the septum (S).

Nasal valve collapse occurs when the upper lateral cartilage collapses medially (arrow) during nasal inspiration.



The nasal valve corresponds to the point of greatest resistance in the entire upper airway [2,3], so it is an important area of focus in the setting of nasal obstruction.

Dynamic collapse of the upper lateral cartilage during inhalation is a common cause of nasal valve compromise and symptomatic nasal obstruction.

[2]. Zambetti G, Filiaci F, Romeo R, et al: Assessment of Cottle's areas through the application of a mathematical model deriving from acoustic rhinometry and rhinomanometric data. Clin Otolaryngol 30:128-134, 2005

[3]. Lenders H, Schaefer J, Pirsig W: Turbinate hypertrophy in habitual snorers and patients with obstructive sleep apnea: findings of acoustic rhinometry. Laryngoscope 101:614-618, 1991

The direct surgical treatment of nasal valve collapse is aimed at lateralizing or stabilizing the upper lateral cartilage.

Numerous techniques are available, including:

- Spreader grafts,
- batten grafts,
- vestibular skin flaps,
- implants,
- And suture dilation techniques [1,4,5].

[1]. Rhee JS, Weaver EM, Park SS, et al: Clinical consensus statement: Diagnosis and management of nasal valve compromise. Otolaryngol Head Neck Surg 143:48-59, 2010

[4]. Rhee JS, Arganbright JM, McMullin BT, et al: Evidence supporting functional rhinoplasty or nasal valve repair: A 25-year systematic review. Otolaryngol Head Neck Surg 139:10-20, 2008

[5]. Golde AR: Rhinoplastic techniques for the nasal valve for the patient with sleep apnea. Op Tech Otol 17:242-251, 2006

The suture dilation techniques share a common theme of retracting the upper lateral cartilages laterally by anchoring to another structure, such as:

- orbital rim [6-8],
- contralateral upper lateral cartilage [9],
- or dorsal nasal soft tissues [10,11].

[6]. Paniello RC: Nasal valve suspension. An effective treatment for nasal valve collapse. Arch Otolaryngol Head Neck Surg 122:1342-1346, 1996

[7]. Friedman M, Ibrahim H, Lee G, et al: A simplified technique for airway correction at the nasal valve area. Otolaryngol Head Neck Surg 131:519-524, 2004

[8]. Friedman M, Ibrahim H, Syed Z: Nasal valve suspension: an improved, simplified technique for nasal valve collapse. Laryngoscope 113:381-385, 2003

[9]. Park SS: The flaring suture to augment the repair of the dysfunctional nasal valve. Plast Reconstr Surg 101:1120-1122, 1998

[10]. Rizvi SS, Gauthier MG: Lateralizing the collapsed nasal valve. Laryngoscope 113:2052-2054, 2003

The existing suture techniques sometimes work very well to open or stabilize the nasal valve, but they have important limitations:

- has an expanse of suture to the anchor point, so the optimal tension can be difficult to gauge intraoperatively.
- the valve suspension technique usually requires hardware to anchor the suture, either with a screw or bone anchor [6-8]
- requires an incision outside the nose.
- restricted to a single retraction and anchor point per side,
- and some anchor to soft tissues, which may be less durable than bone anchoring.

[6]. Paniello RC: Nasal valve suspension. An effective treatment for nasal valve collapse. Arch Otolaryngol Head Neck Surg 122:1342-1346,1996

[7]. Friedman M, Ibrahim H, Lee G, et al: A simplified technique for airway correction at the nasal valve area. Otolaryngol Head Neck Surg 131:519-524, 2004

[8]. Friedman M, Ibrahim H, Syed Z: Nasal valve suspension: an improved, simplified technique for nasal valve collapse. Laryngoscope 113:381-385, 2003



# The nasal valve stabilization (NVS)

A new suture technique available to stabilize the collapsible nasal valve while addressing some of the aforementioned challenges:

- It is simple,
- requires only intranasal incisions,
- provides secure bony anchor points,
- easily allows multiple retraction and anchor points,
- does not change nasal appearance,
- and leaves no permanent foreign body.

# Indications

Technique can be performed in isolation or in combination with other nasal procedures.

Indicated as a primary procedure in the setting of isolated nasal valve collapse without other nasal deformities.

If other structural abnormalities contribute to nasal valve compromise, then valve stabilization can be performed:

- with other nasal procedures (eg, septoplasty),
- or it can be reserved for a secondary procedure.

NVS is also easily performed in patients who have had previous nasal surgery, even if there were multiple or complex previous surgeries.

# Assessment of nasal valve compromise

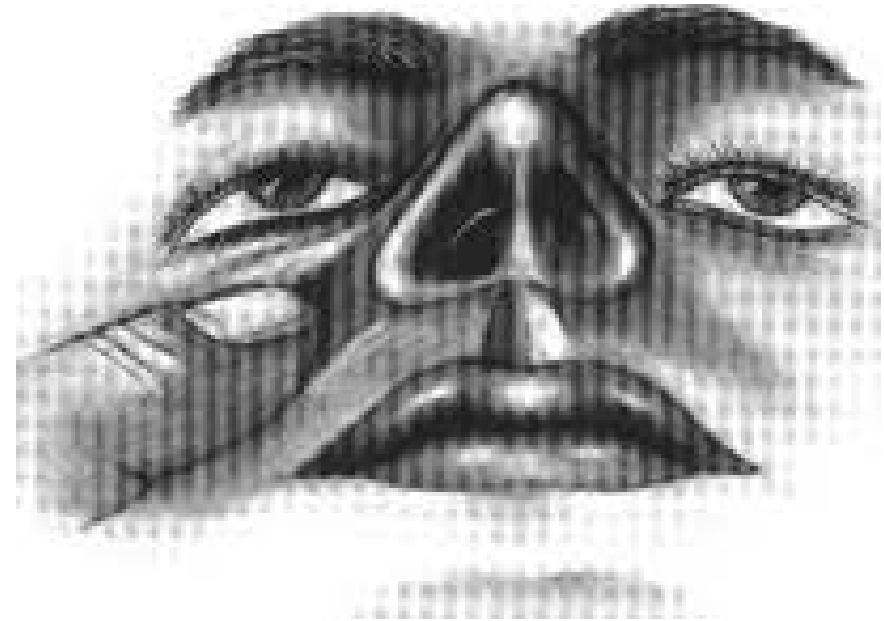
Includes:

- Symptomatic and/or audible restriction of airflow on inhalation, especially if the upper lateral cartilage visually collapses,
- nasal endoscopy facilitates visualization of collapse by allowing visualization without a speculum (which can inadvertently stabilize the nasal valve),
- A Cottle maneuver,
- A valve stabilization test.

# The Cottle's maneuver (CM)

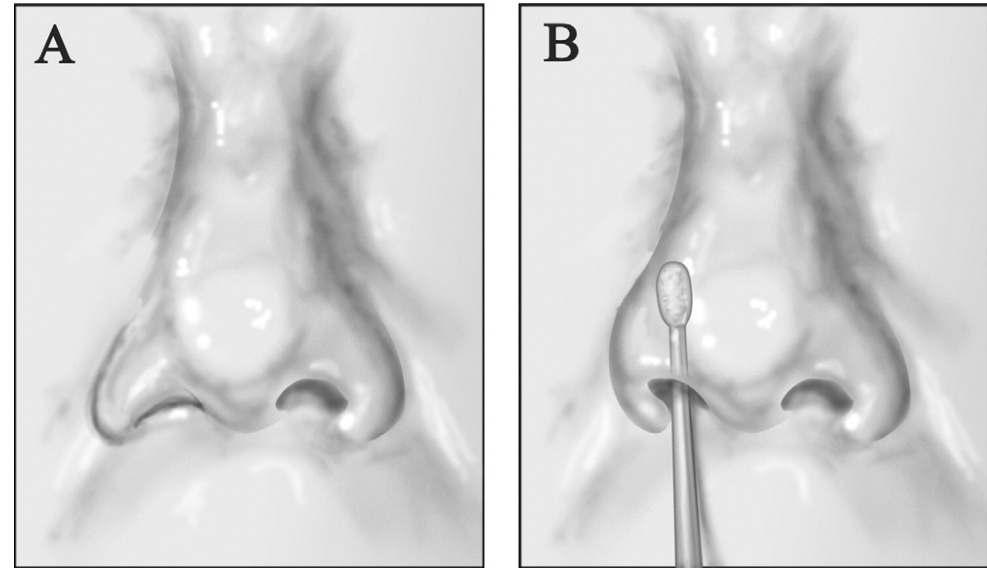
Is a test in which the cheek on the side to be evaluated is gently pulled laterally with one to two fingers to open the valve.

This test is used to determine if the most significant site of nasal obstruction is at the valve or farther inside the nasal cavity.



# Valve stabilization test

Stabilization of the right upper lateral cartilage with a cotton-tip applicator prevents nasal valve collapse and helps determine the effect of nasal valve stabilization.

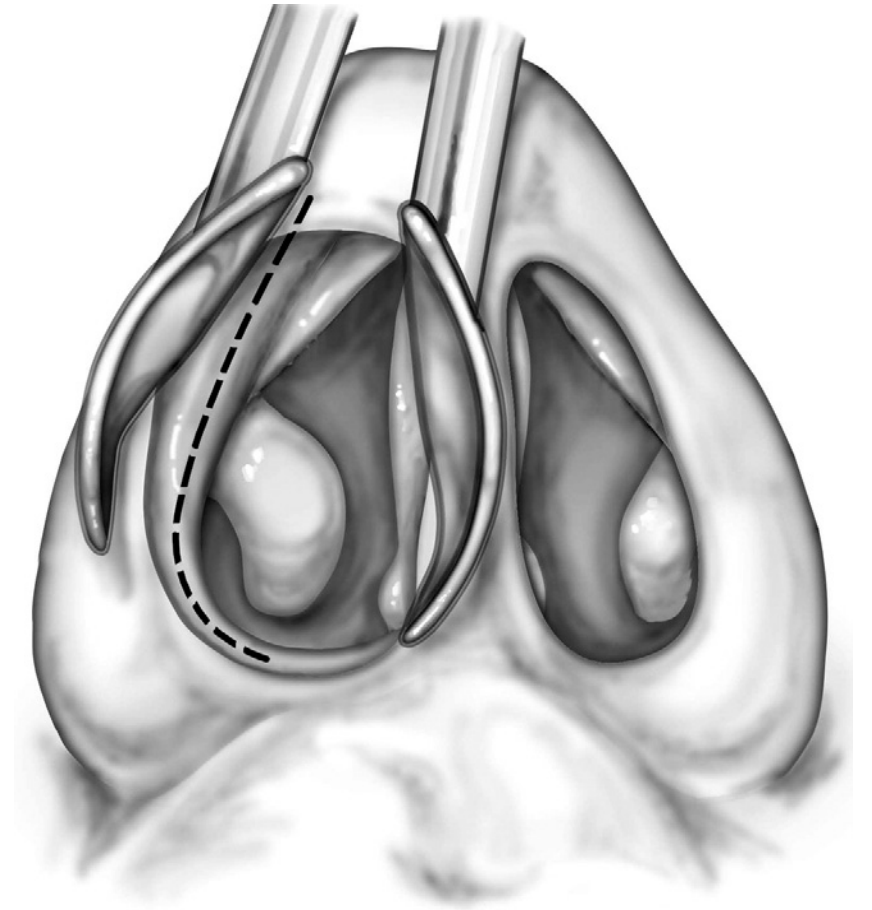


A, Collapse of right nasal valve during inspiration.

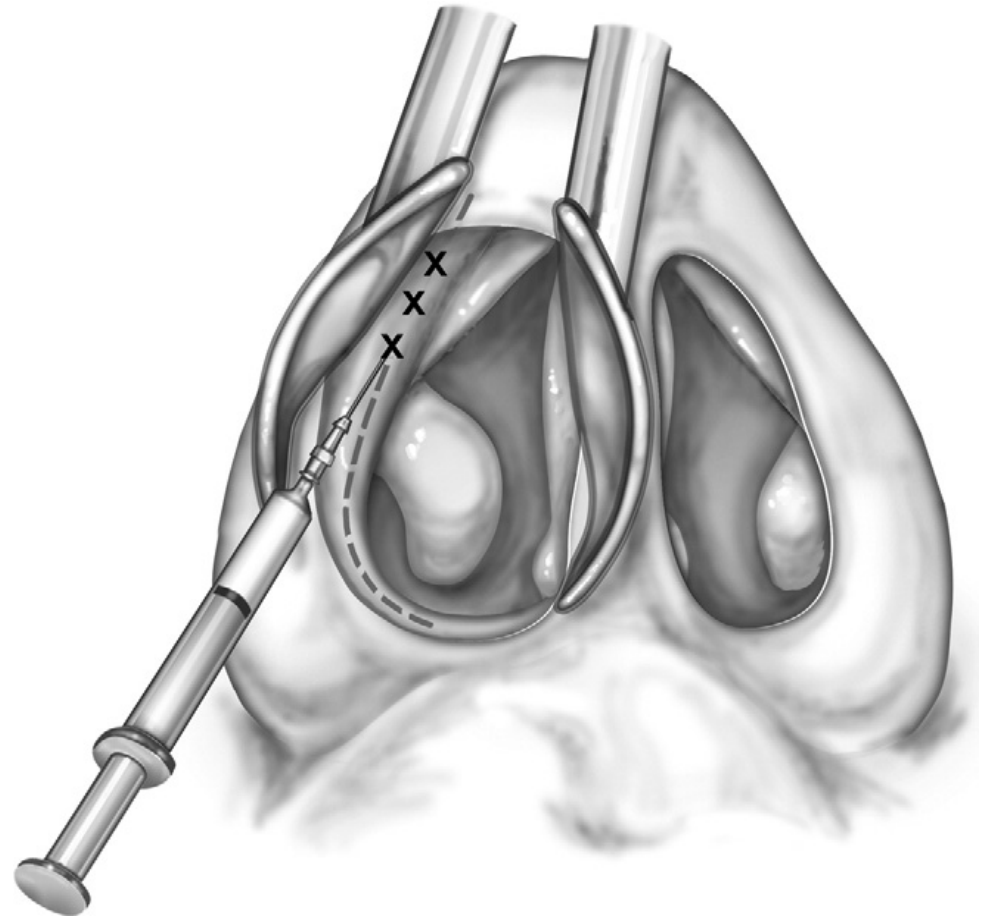
B, Improved airflow with nasal valve stabilization confirming nasal valve compromise and possible improvement with nasal valve stabilization procedure.

# Technique

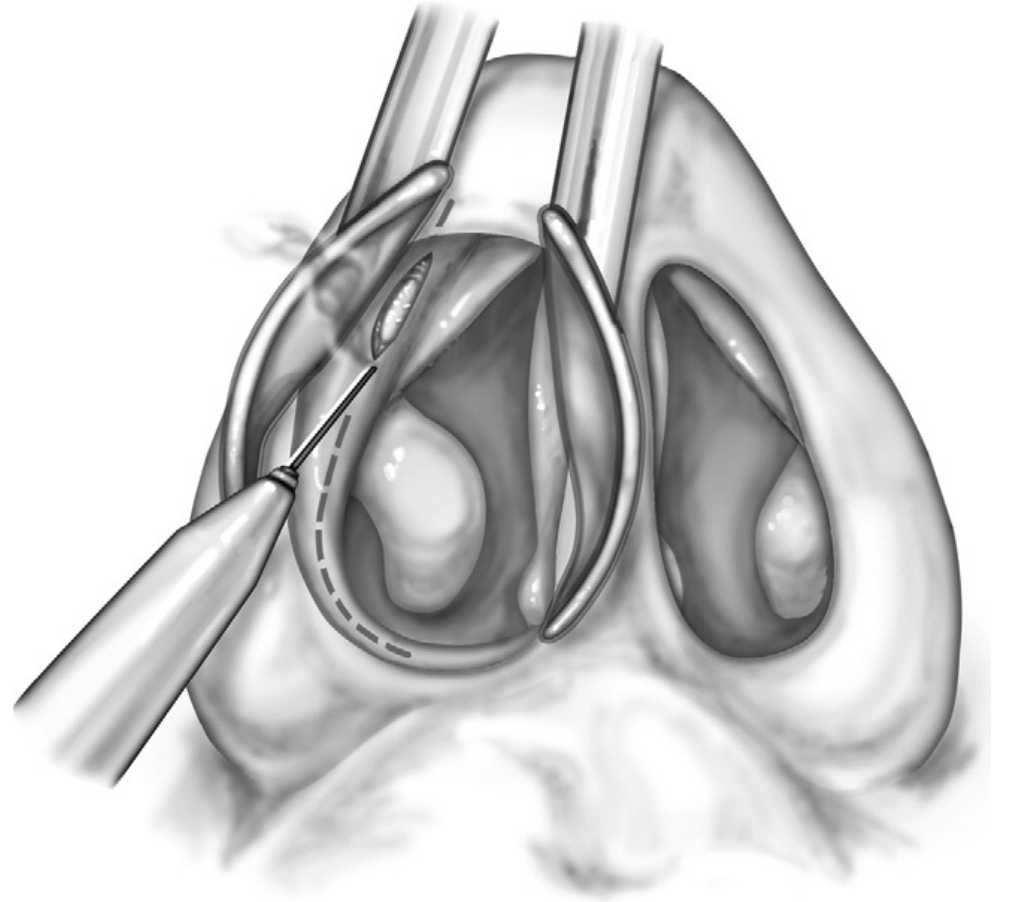
- The procedure is typically performed in the operating room under general anesthesia; however, it can be performed under local anesthesia.
- Preoperative topical decongestant is applied to the nasal mucosa.
- The operative set up is similar to other nasal procedures, such as turbinate submucous resection.
- Transverse (horizontal) speculum placement easily exposes the piriform rim



- A mixture of local anesthetic and vasoconstrictor is injected into the soft tissue overlying the piriform rim while visualizing directly by anterior rhinoscopy

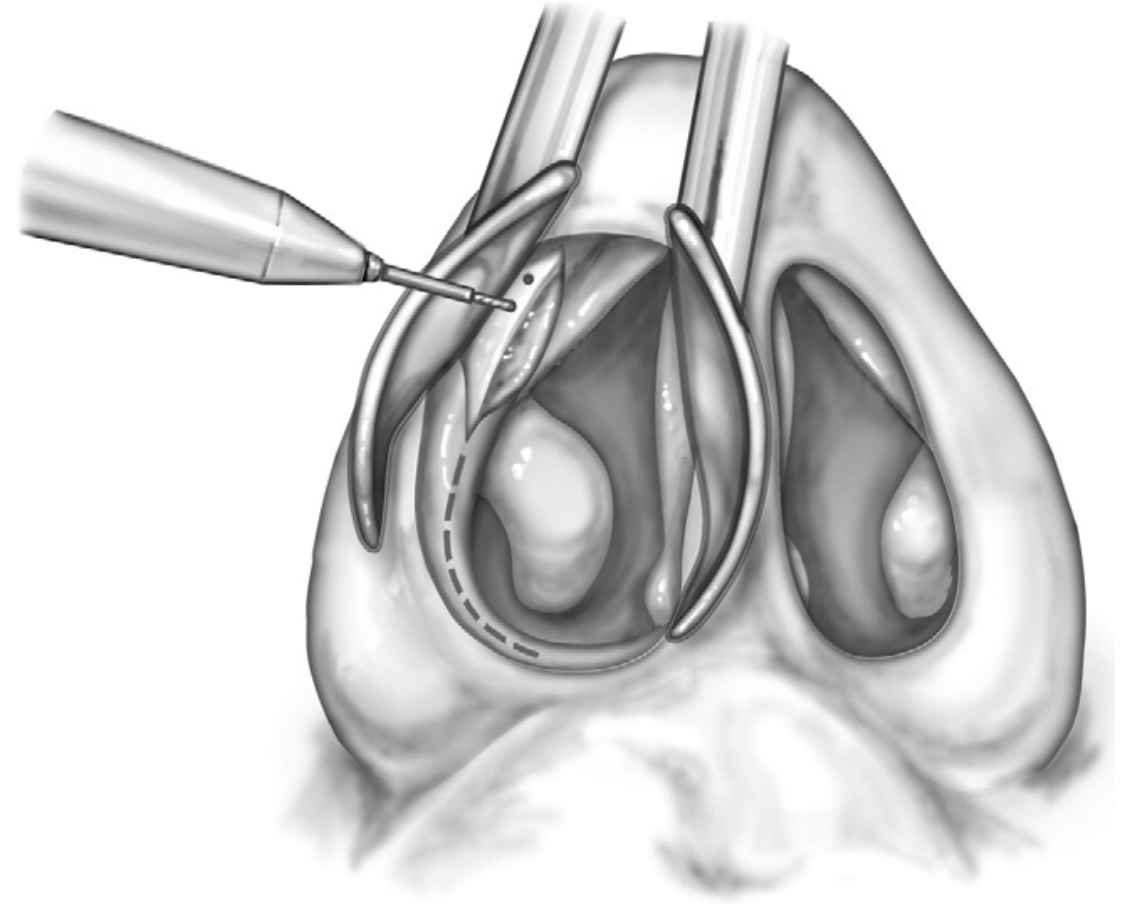


- After adequate time for vasoconstrictor effect, a needlepoint electrocautery incision is made over the piriform rim up toward the upper lateral cartilage and nasal bone

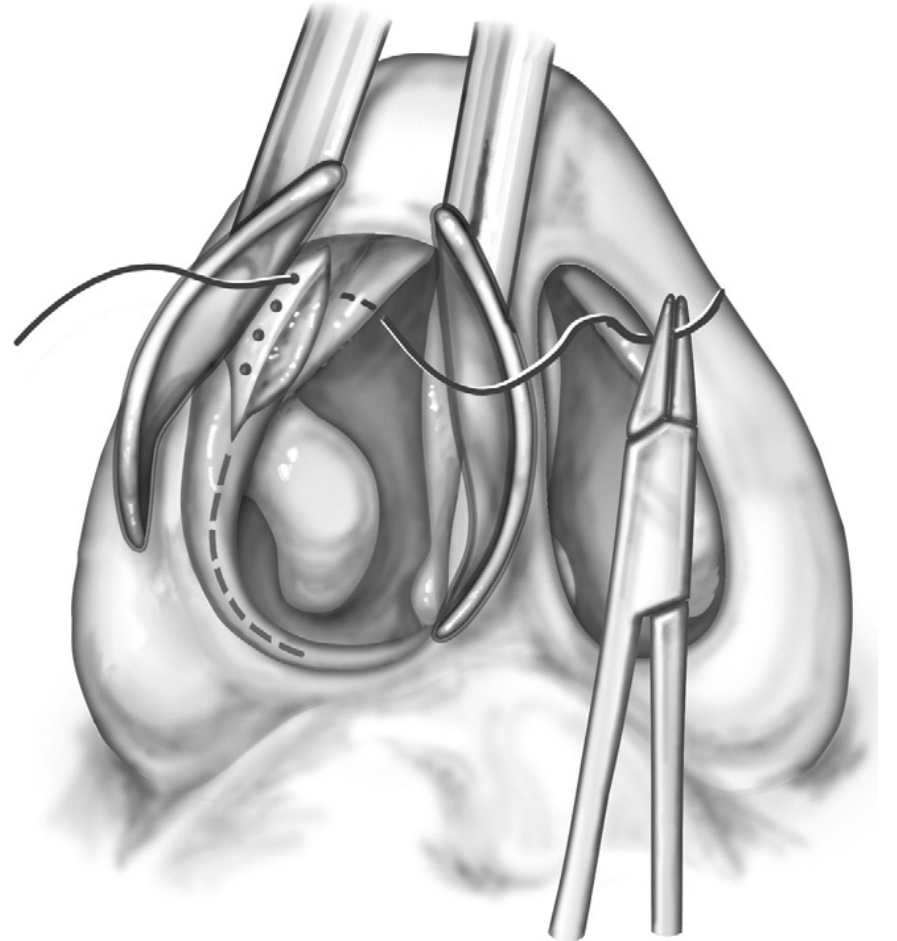




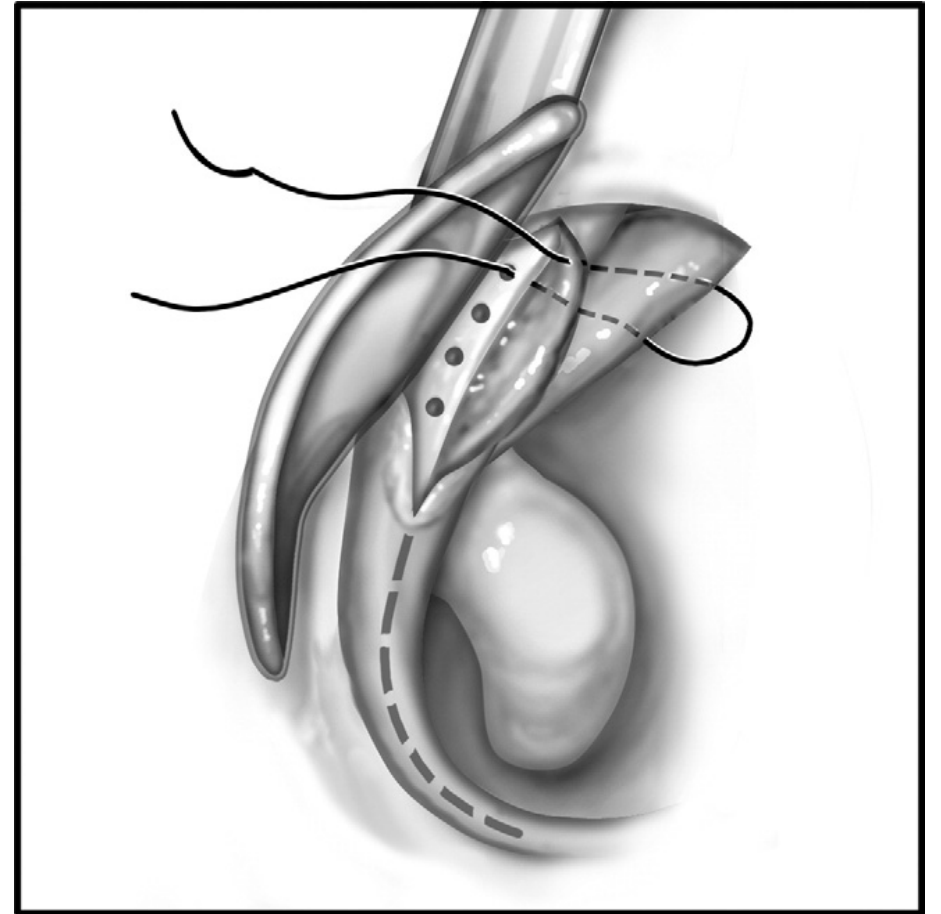
- Subperiosteal dissection along the medial and lateral aspects of the rim exposes 5 mm of the bony rim up toward the nasal bones and inferiorly toward the attachment of the inferior turbinate bone
- A short, small drill bit (eg, 6-mm length, 0.76-mm diameter) is used to drill 3 or 4 holes in the piriform rim 1 to 2 mm from the bony rim
- The nasal speculum can be used to protect the nasal soft tissues while drilling, and only a small amount of irrigation is needed. It is preferable to have one or more drill holes superior to the caudal edge of the upper lateral cartilage, if possible.



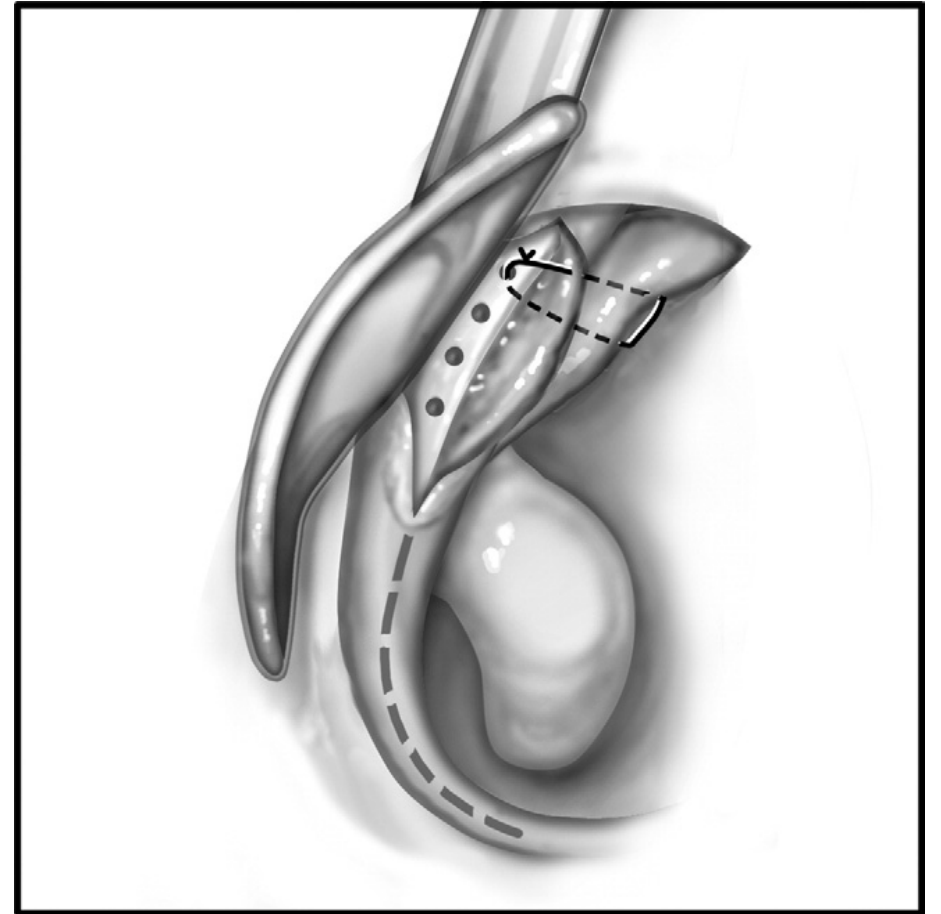
- A suture is used to anchor the upper lateral cartilage to the bony rim. The suture is passed through the top drill hole from lateral to medial, then through the upper lateral cartilage into the nasal cavity



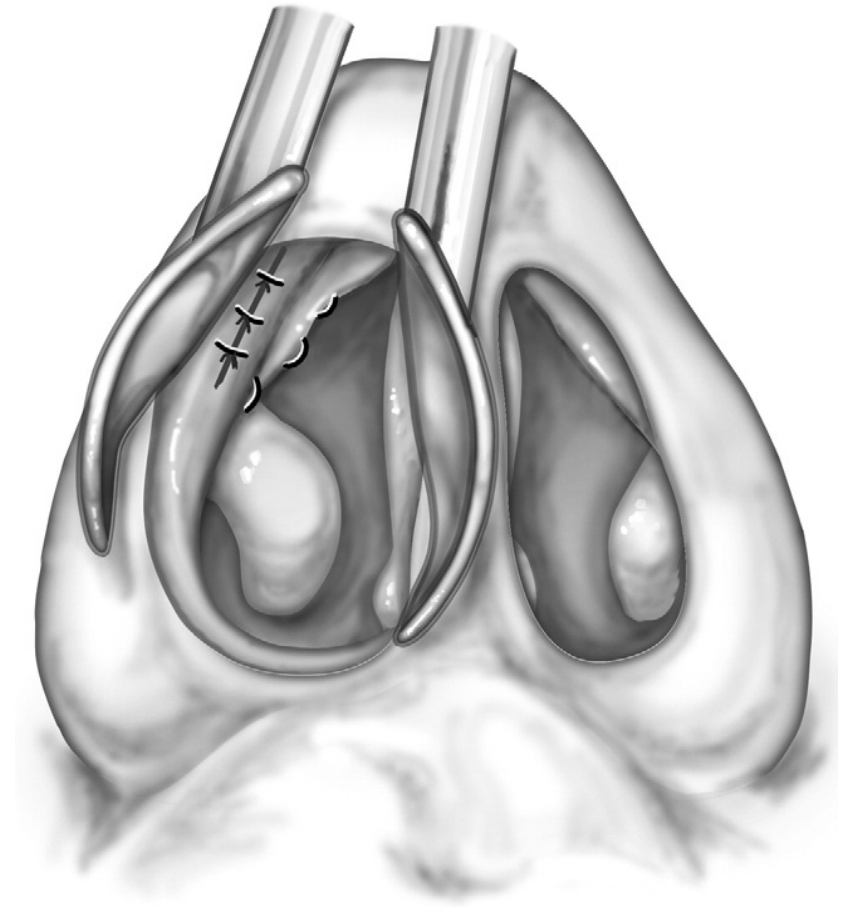
- The suture is passed back through the nasal mucosa overlying the upper lateral cartilage, through the cartilage into the surgical wound anterior to the bony rim



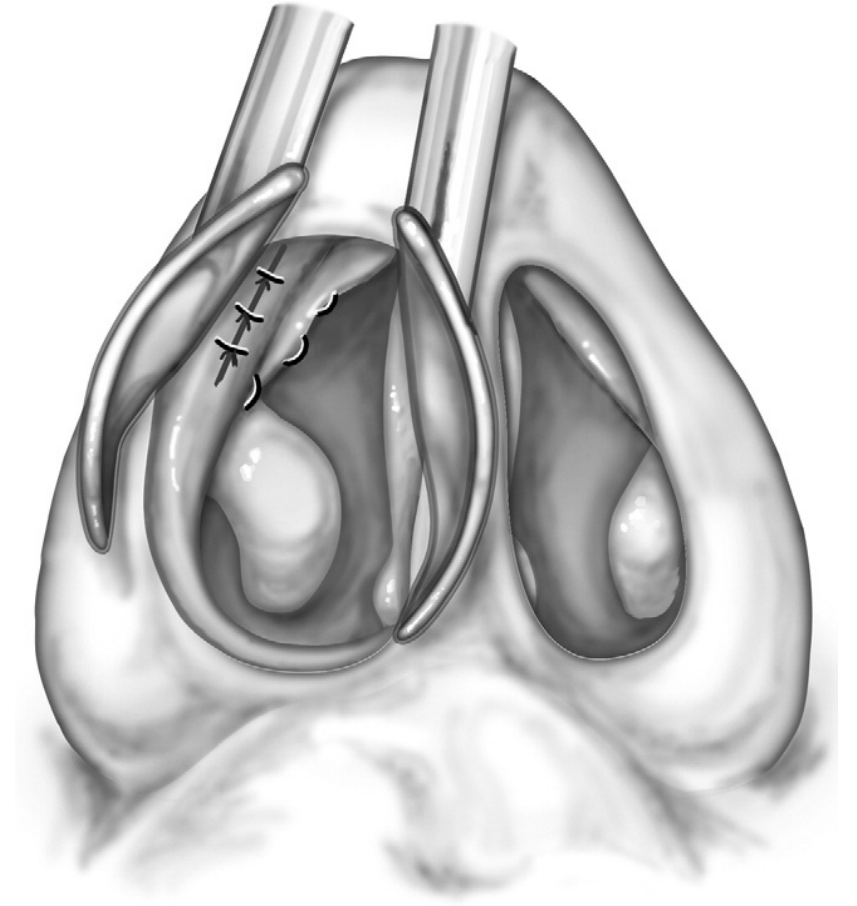
- This results in a loop of suture through the upper lateral cartilage and around the bony bridge between the drill hole and edge of the piriform rim



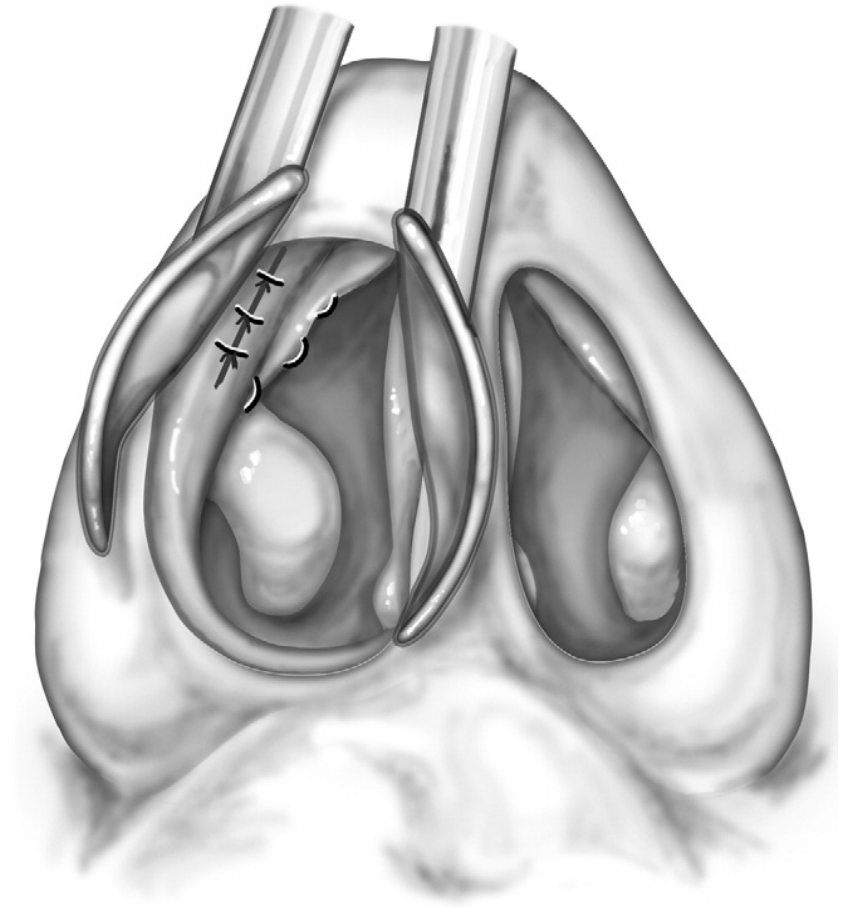
- There is exposed suture along the mucosa of the upper lateral cartilage.
- This segment of suture can be buried submucosally by incising the underlying mucosa superficially.
- The suture is tagged, and another 1 to 3 sutures are passed through the other holes to create multiple anchor points.
- Usually only the superior 2 sutures are passed through the upper lateral cartilage, and the inferior 1 to 2 sutures are passed through the lateral nasal mucosa to pin it laterally to the bony aperture.



- The sutures are tied tightly and cut at the knot.
- If the patient also has an alar rim collapse (“external nasal valve collapse”), then the suture can also be passed through alar tissue to help stabilize it, but care must be taken to avoid alar distortion when tightening the suture.
- The incision is closed with a fine absorbable suture (eg, 5-0 chromic gut suture), and the same procedure is performed on the contralateral side if needed.



- Also a 2-0 polyglycolic acid (absorbable, synthetic, braided) suture can be used on a 17-mm, half-circle, taperpoint needle to stabilize the upper lateral cartilage.
- Even after the suture eventually reabsorbs, the valve stabilization appears to hold, presumably related to submucosal scar formation along the suture tract and surgical dissection.
- Alternatively, a permanent suture, such as 3-0 braided polyester suture can be used, but it adds the risk of future granuloma or foreign body reaction.



# Complications

- One of the advantages of this technique is the low risk of complications.
- The most common complication is incomplete treatment effect or persistent nasal valve collapse.
- The temporarily exposed intranasal suture can become crusted, but this problem is managed easily with petrolatum ointment application twice daily until suture is reabsorbed or submucosal placement of this segment of suture.
- Occasionally granulation tissue will form at the suture site, but it typically resolves as the suture is reabsorbed. If needed, silver nitrate cautery can be applied to granulation tissue.



# Discussion (I)

The nasal valve stabilization technique is a variation of the nasal valve suspension technique, but it offers some potential advantages:

- The stabilization technique easily allows multiple stabilization points.
- It does not require an extranasal incision, and it does not change the nasal appearance.
- It takes guesswork out of how tight to tie the sutures.
- It anchors strongly to bone without any permanent foreign body.
- It is a minor procedure requiring a simple intranasal incision.

## Discussion (II)

- It can be performed in isolation or in combination with other nasal procedures.
- It can be employed as a primary procedure or as a secondary procedure after prior nasal surgery.
- It can often be performed in patients who have had multiple prior rhinoplastic procedures when other valve procedures are risky or not possible.
- Since it leaves no permanent foreign body and requires little dissection, longterm risks are minimal.

# Discussion (III)

However, the nasal valve stabilization is not perfect:

- It only addresses dynamic collapse and not anatomic narrowing of the nasal valve area.
- It often provides only partial valve stabilization, just like every other nasal valve surgical techniques.