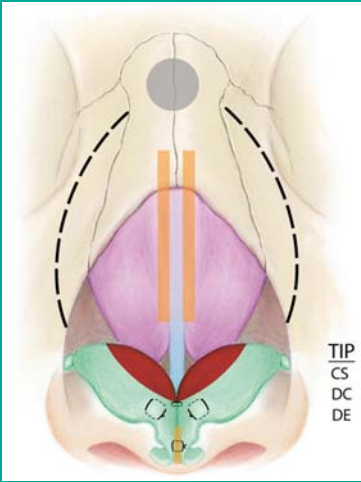


A Basic Rhinoplasty Operation 2



Why is rhinoplasty so difficult? The answer is the wide variation in the patient's nasal anatomy and aesthetic desires. For the surgeon, the challenge is mastering the endless number of operative techniques available. Thus, the question becomes can one devise a basic rhinoplasty operation? A former resident who was 3 years into private practice made the following request: "Can you give me a basic rhinoplasty operation with which I can get good results and have few revisions?" My answer was quick and blunt – "It is impossible because both the anatomy and the requisite techniques are too varied." Despite my negativity, the desire to develop a basic rhinoplasty operation has continued to intrigue me. Gradually, the fundamentals of a standard rhinoplasty operation began to crystallize. The following operation is intended for the average well-trained plastic surgeon. It can be expanded to fit a large range of nasal deformities. However, it requires that the surgeon accepts two principles. First, the surgeon must begin by doing only those cases which fit within their surgical comfort zone. Second, the surgeon must implement a progressive approach for learning rhinoplasty surgery. One begins with easier Level 1 cases and then advances to the more challenging Level 2 deformities before ultimately taking on the most difficult Level 3 problems. Distribution wise, perhaps 70% of the primary cases are Level 1, 25% are Level 2, and only 5% are Level 3. A fundamental operation will be presented in a step-by-step fashion in this chapter and its progressive adaptations for the three levels of deformities will be detailed in the rest of the text. It is important to select only those steps that are appropriate for a specific case.

Introduction

Remember the 95% rule – 95% of rhinoplasty articles and lectures deal with the most esoteric 5% of noses, yet 95% of surgeons do not want to do the most difficult 5% of noses. This basic rhinoplasty operation is designed to allow the surgeon to do surgery for 95% of primary patients seen by a surgeon in the private practice of aesthetic surgery.

Consultation

During the initial consultation, I ask myself two critical questions about the patient. First, will a rhinoplasty make a significant improvement in this patient's nose? Second, do I want this person in my practice? If the answer is no to either question then I do not do their surgery. Rhinoplasty is not a frivolous operation; the procedure must be considered carefully by both the patient and the surgeon. The patient's goals should be to get a realistic assessment of the surgical risk to reward ratio and evaluate whether they feel comfortable with you being their surgeon. Unfortunately, surgeons too often concentrate on the technical challenge and the economic benefit of doing every nose, yet the risks of selecting the wrong patient is very real for the surgeon ranging from frustration to misery to physical abuse.

Nasal Deformity. In primary cases, patients are usually very accurate in defining what is wrong with their nose, but often very nonspecific about what they want. The easiest patients are those requesting elimination of obvious deformities (bump on profile, round tip), while the most difficult are those who are unable to say exactly what they desire or those who demand a specific "look." Essentially, one must get patients to commit to what they want. For this reason, I have the patient tell me what three things should be improved in the order of importance. Next, I examine the nose in detail and make my list of what must be done to make the nose attractive and to achieve balance with the face. Perhaps 90% of all the primary consultations have a correctable nasal deformity on evaluation. The other 10% are attractive females with minimal deformities, males seeking "model" refinements, and patients wanting a "major change" when only a limited improvement is realistic.

Patient Factors. It is important to assess the patient's motivation. Open-ended questions should be asked as they will often reveal the patient's motivation. "What do you not like about your nose?" "Why do you want surgery at this time?" "What effect will a rhinoplasty have on your life?" It is extremely important to "hear" what the patient is saying psychologically rather than merely listening to the words. Which patients do I reject for primary rhinoplasty? These would include the overly narcissistic male, the perfectionistic female who will never be satisfied, and the unhappy patient who thinks that the operation will change his or her life. Once you choose to operate, you must provide the care and concern that the patient requires, not the amount that is reasonable. I have learned the hard way that "the pre-op course is finite, but the post-op course is infinite."

Analysis. Given the choice, would most surgeons rather be a master technician with golden hands or a strategic tactician with a critical aesthetic eye? In rhinoplasty as in chess, it is the thought process before the manipulation of the pieces that is critical. If one fails to recognize that the radix is low, then the dorsum will be lowered excessively resulting in a nose job appearance. In contrast, the simple addition of a fascia graft to the radix allows a more limited dorsal reduction producing a more natural, elegant, unoperated look. The difference is not surgical skill, but rather the design of the operative plan based on preoperative analysis.

Prior to my evaluation, I hand the patient a mirror and ask them to show me what bothers them the most, preferably in the order of importance. I write these down on the operative planning sheet and they become the cornerstone of the operative plan assuming they are correctable. After a thorough internal and external exam, I do a top-down region exam.

Radix and Dorsum. The radix is analyzed on lateral view for both the radix area (from glabella to lateral canthus level) and nasion (the deepest point in the nasofrontal angle). The critical decision is whether the radix needs to be maintained, augmented, or reduced. Fortunately, no modification is necessary in most cases (82%). Next, the dorsum is evaluated for height and width, while the bony base is assessed for width. The key determinant of dorsal height is the nasofascial angle, which is measured from nasion to tip. The desired profile line is slightly curved for females, straight for males. On anterior view, the width of the parallel “dorsal lines” is roughly the same as the philtral columns or tip-defining points, 6–8 mm for females, 8–10 mm for males. The maximum base bony width of the nose is marked as the “X-point” and should be less than the eyes’ intercanthal width.

Tip. Tip analysis is complex and will be discussed in great depth in Chapters 4 and 8. The following is a basic overview. The “lobule” is the entire area overlying the alar cartilages, whereas the “intrinsic tip” incorporates just the area between the tip-defining points transversely and between the columella breakpoint and supratip point vertically. I focus on these characteristics: (1) the intrinsic factors of volume, definition, and width; (2) the extrinsic/intrinsic factors of rotation and projection; and (3) the overall factors of tip shape and skin envelope. I assign a “value” to each: ideal, minor, moderate, or major deformity in both a positive and negative direction. Then, I make a critical decision: is the tip inherently attractive or do I need to change it. As will be discussed extensively in the chapters on tip surgery, I feel that most surgeons should learn an open tip suture technique which can be expanded to fit a wide range of tip deformities. At the consultation, I draw the anticipated tip surgery procedure including the various sutures and any tip refinement grafts (TRG).

Base. The base of the nose consists of alar bases, nostrils, and columella. Numerous factors must be assessed including caudal septum, anterior nasal spine, and maxilla. The most common decision is whether to reduce alar base width or nostril size. In general, the alar bases should be narrower than the intercanthal width and the nostril sills should not be excessively visible on anterior view. I have evolved a simplified approach of three procedures – nostril sill excision, alar wedge excision, or combined to deal with these problems. Although conservative in the amount of excision, one should not limit their application. Preexisting nostril asymmetry should be pointed out to the patient preoperatively as only a slight improvement is realistic.

Operative Planning

Formulation of an operative plan involves selecting specific surgical techniques which are combined to produce the optimal *individualized* operative sequence for the specific patient (Fig. 2.1). The first step is to define the patient's goals and the surgeon should write out the proposed operative sequence following a thorough internal and external exam (Op Plan #1). Nasal photographs are taken and individual views are printed to allow detailed planning using classic landmarks and angles defining actual, ideal, and realistic goals (Op Plan #2). When the patient returns for the pre-op visit, the nose is examined from the surgeon's perspective with the questions being: What do I not like about the nose (the negatives)? What are the aesthetic possibilities for this nose (the upside goal)? What will the patient's tissue and my experience allow me to achieve (the reality check)? (Op Plan #3) Then I review the photographs of the desired noses that the patient has brought. At the end of the pre-op visit, the final operative plan has evolved (Op Plan #4). A step-by-step operative plan is written out and it will be posted in the operating room with the photographic analysis of the patient. During the actual operation, changes may occur on a "sliding scale" but rarely is a step dropped. The final operation is recorded both by a check box table database plus drawings and dictated (Final Operation). The data table with drawings is checked at each post-op visit with emphasis on surgical cause and effect.

Operative Sequence

The advantage of a standard operation is that the operative sequence is largely predetermined (Table 2.1). I favor a dorsum to tip sequence. I first establish the ideal profile line and then fit the tip to it. I do the dorsal reduction prior to the septal surgery as it minimizes disjunction of the critical septal strut. Alar base modifications are done after all incisions are closed and alar rim grafts (ARG) follow any alar base modification. Initially, the surgeon should write out an operative sequence for each patient prior to surgery and then post it in the operating room below the patient's photographs.

Markings

On the day of surgery with the patient sitting up, I mark the following: ideal dorsal profile line, x-point, lateral osteotomies, ideal tip point, transcolumellar incision, and any alar base incisions.

PRINCIPLES

- One must correct the deformities that bother the patient or they will not be happy.
- The more detail the pre-op planning is, the smoother the operation.
- The simpler the operative plan is, the smaller the risk. Always design an operative plan with maximum gain and minimum risk.
- Write out your operative sequence step by step and put it up in the operating room – know what you are going to do.

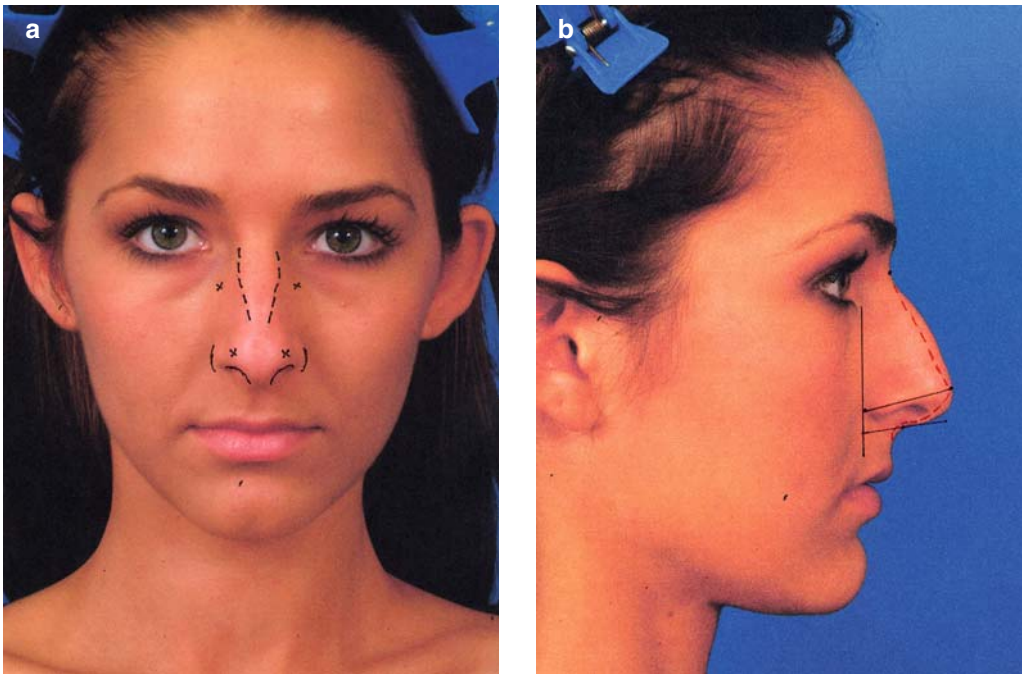


Fig. 2.1 (a) Patient analysis (b) Operative planing 

Table 2.1 Operative sequence of a basic rhinoplasty operation

1. Essentials – 2.5x loupes, fiberoptic headlight, own instruments
2. Anesthesia – General with appropriate monitors
3. Local injection followed by preparation – wait 10–15 min
4. Remove intranasal nasal pack and shave vibrissae
5. Open approach using infralobular and transcolumellar incisions
6. Elevation of skin envelope
7. Septal exposure via transfixion incision and extramucosal tunnels
8. Reassess operative plan based on alar and septal anatomy
9. Creation of symmetrical alar rim strips
10. Incremental hump reduction – rasp:bone, scissors:cartilage
11. Caudal septum/ANS excision (Optional)
12. Septal harvest/septoplasty
13. Osteotomies
14. Graft preparation
15. Spreader grafts (Optional)
16. Columellar strut and suture
17. Tip sutures with optional add-on grafts (excised alar cartilage)
18. Closure
19. Alar base modification (optional)
20. Alar rim grafts (ARS) (optional)
21. Doyle splints, external cast, and nasal block

The basic operation is a relatively standard sequence that I use routinely, but with virtually unlimited variations. The operative sequence is individualized for each primary rhinoplasty with certain steps deleted as indicated. Although every step of the basic rhinoplasty operation does not need to be done in each patient, I am convinced each step will be needed in your first 25 rhinoplasties.

Anesthesia

I do the vast majority of my rhinoplasties under general anesthesia because this is what the patient and I prefer. Certain precautions have improved the safety record of general anesthesia: (1) a Raye tube is used and the tube is marked with tape at the lip line, (2) alarm sensors can determine any disconnection of the tube within 5 seconds, and (3) oxygen and carbon dioxide monitors are routinely used. Additional precautions include ointment in the eyes to prevent corneal abrasion and a throat pack of wet 2 in. gauze to prevent ingestion of blood. In nonallergic patients, 1 g of Ancef is given intravenously during the operation.

Once intubation is complete, the external and internal areas of the nose are thoroughly scrubbed with Betadine paint by the surgeon. Then, the local anesthesia with its vasoconstrictive agent (1% xylocaine with epinephrine 1:100,000) is injected (Fig. 2.2). The injections are done in two components: a picture frame block to reduce the regional blood supply and then the specific areas of surgery. This method also produces an effective sensory block. Specifically, the five areas for injection consist of (1) tip and columella, (2) lateral wall, (3) dorsum/extramucosal tunnels, (4) incision lines, and (5) septum if appropriate. First, the needle is inserted from the vestibule toward the infraorbital foramen with injection occurring on withdrawal. Three sites are injected: infraorbital foramen (infraorbital vessels), lateral nasofacial groove (lateral facial vessels), and alar base (angular vessels). The columella base is injected extending outward below the nostril sills (columellar vessels). The needle is then inserted along the top of the septum in the area of the extra mucosal tunnels (anterior ethmoidal vessels). On withdrawal, the needle passes along the dorsum to facilitate future dissection and terminates in the radix area on either side (infratrochlear vessels). Next, the access incisions are injected with minute amounts of local anesthesia. The septum is blocked from posterior to anterior. For an open approach, I inject the lobular skin envelope over the alar cartilages from the tip extending laterally and down the columella. The nasal vibrissae are most easily trimmed with a scissors. The internal nose is packed with 18 in. strips of 0.5 in. gauze wetted with 4 cc of one of the three solutions: 4% cocaine, 1% xylocaine with epinephrine 1:100,000, or Afrin. I prefer 4% cocaine, but any of the three is effective.

PRINCIPLES

- Use general anesthesia with appropriate monitors and a throat pack.
- Do a thorough intranasal prep with Betadine prior to injection.
- Do a five-area injection of local anesthesia based on the vascular anatomy.
- With an open approach, do not hesitate to hydrodissect the entire lobule (1.5–2 cc). It will disappear quickly.
- Pack the nose with 0.5 in. gauze soaked in a topical vasoconstrictive agent.
- Once injected, wait 15 min. Do the definitive prep and drape.

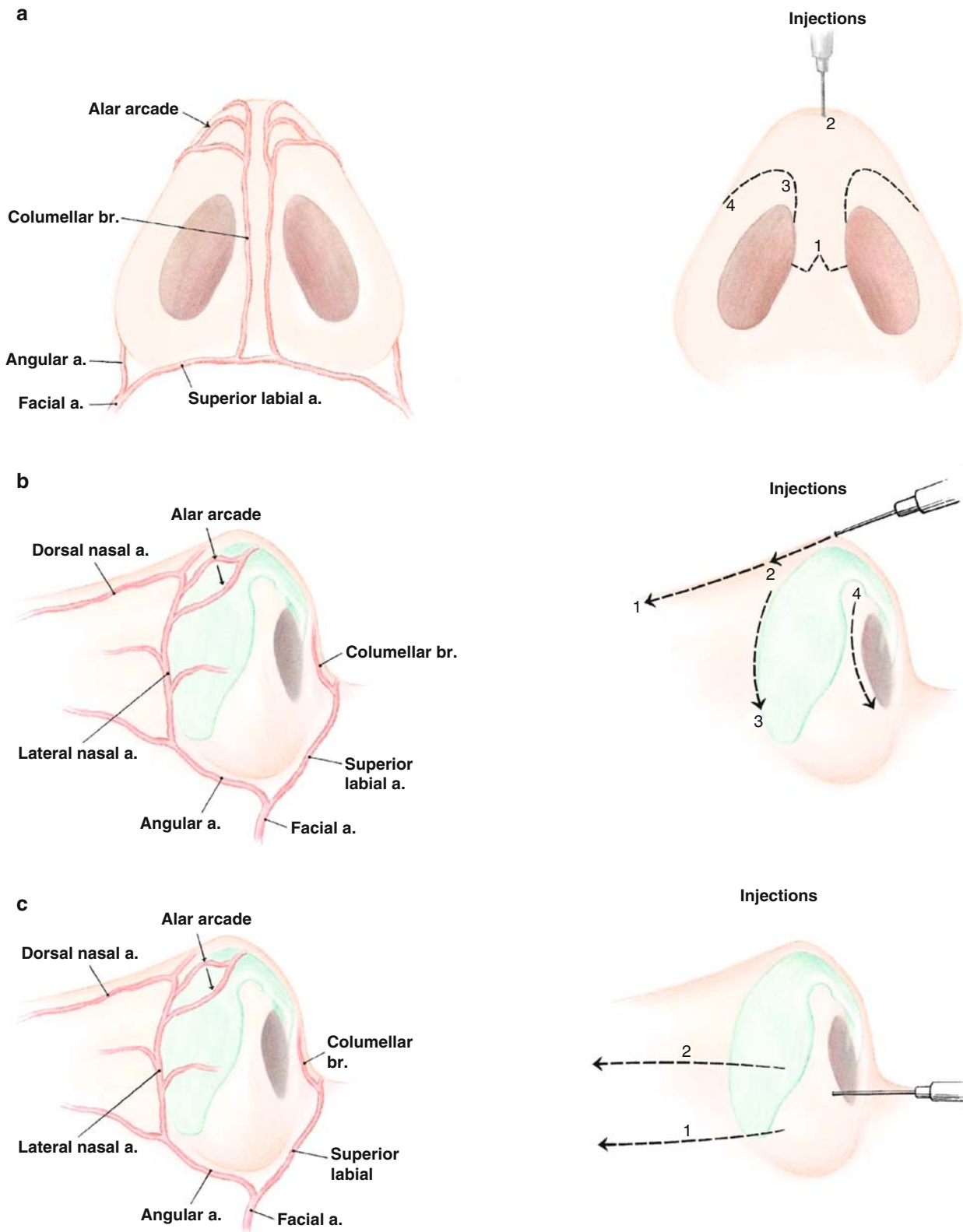



Fig. 2.2 (a-c) Local anesthesia 

Open Approach

Immediately prior to the incisions, I redraw the transcolumellar incision and reinject the columellar with local anesthesia. Over the years, I have tried virtually all the standard columellar incisions, but I still prefer Goodman's original inverted-V with wings. A small 3 mm equilateral inverted-V is drawn whose apex is at the narrowest point of the columellar (Fig. 2.3a–d). The transverse wings are drawn across and behind the columellar pillars. The standard infracartilaginous incision consists of three parts: lateral crura, dome, and columella. It must be emphasized that this incision *follows the caudal border of the lateral crura* and not the nostril rim. Using a 10 mm double hook, the surgeon retracts the alar rim and then provides counterpressure with the ring finger. The #15 blade is then placed at the dome and the lateral cut is done following the caudal border of the lateral crura. Then the double hook is readjusted and counterpressure is placed on the dome allowing the incision to be carefully “scratched” high in the vestibule from the dome down onto the columellar to the level of the transcolumellar incision. Holding the columella with the nondominant hand, a #11 blade is used to make the inverted-V incision and then a #15 blade is used to make the transverse wings being careful to “scratch” through the skin overlying the cartilage.

Columella-to-Tip Exposure. With the incisions completed, a “columella to tip” dissection technique is used with three-point traction (Fig. 2.3e, f). The assistant retracts the alar rim upward with a small double hook while retracting the dome downward with a single double hook. The surgeon then elevates the columellar skin with a small double hook and dissects upward using the angled converse scissors. It is often necessary to switch back and forth between the two sides, and to use extreme caution as one approaches the domes. The skin envelope is retracted upward with a Ragnell retractor and the area overlying the septal angle is entered to expose the glistening cartilaginous vault. Hemostasis is done as required.

Bidirectional Exposure. Although the “columella to tip” exposure method is the classic one, the “bidirectional” exposure technique is easy to learn and extremely useful in scarred secondary tips (Fig. 2.3g, h). Essentially, one makes the standard infracartilaginous incision and then dissects over the lateral crura using blunt tip tenotomy scissors. Then the scissor tips are turned perpendicular and spread to allow rapid avascular dissection which is continued toward the domes. The soft tissue is elevated from the transcolumellar incision upward. The bidirectional exposure allows the dome to be preserved.

PRINCIPLES

- The location of the transcolumellar incision is more important than its shape. It's apex is at the narrowest point of the columellar.
- The infracartilaginous incision follows the caudal border of the alar cartilage – a true nostril rim incision can be a disaster.
- Do not hesitate to inject 1–2.0 cc of local anesthesia into the tip lobule – it facilitates dissection and will dissipate quickly.

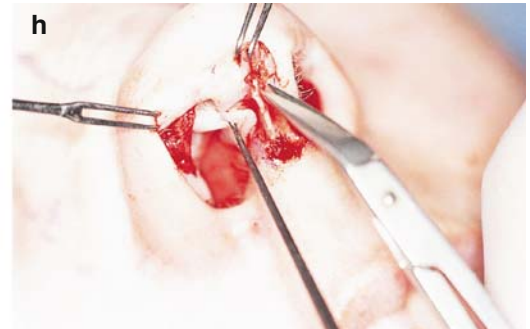
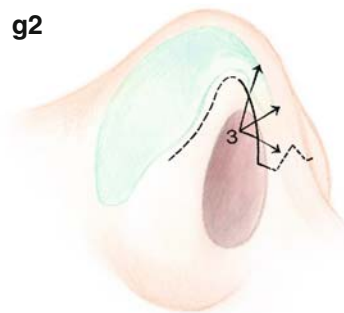
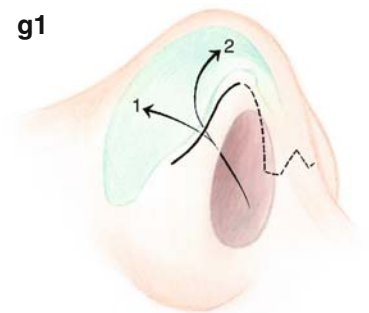
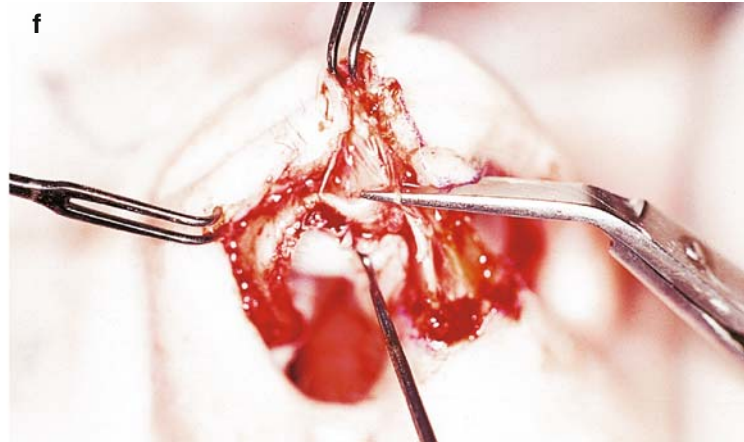
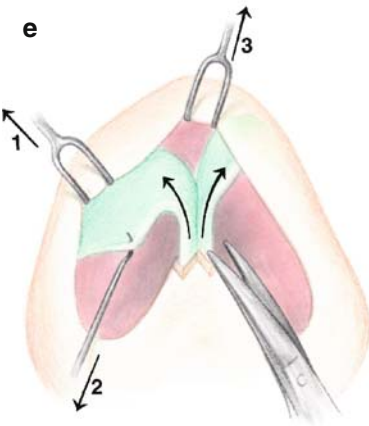
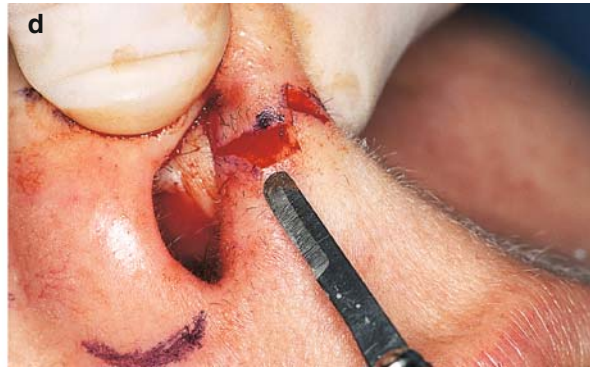
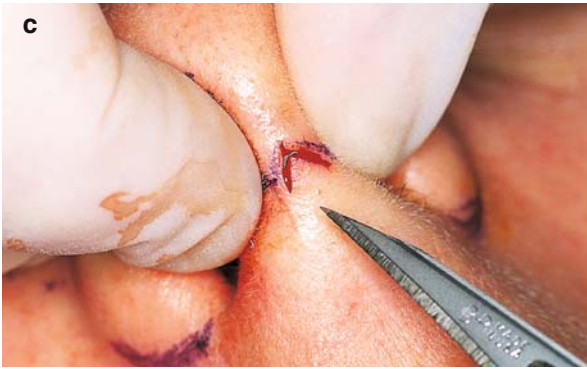
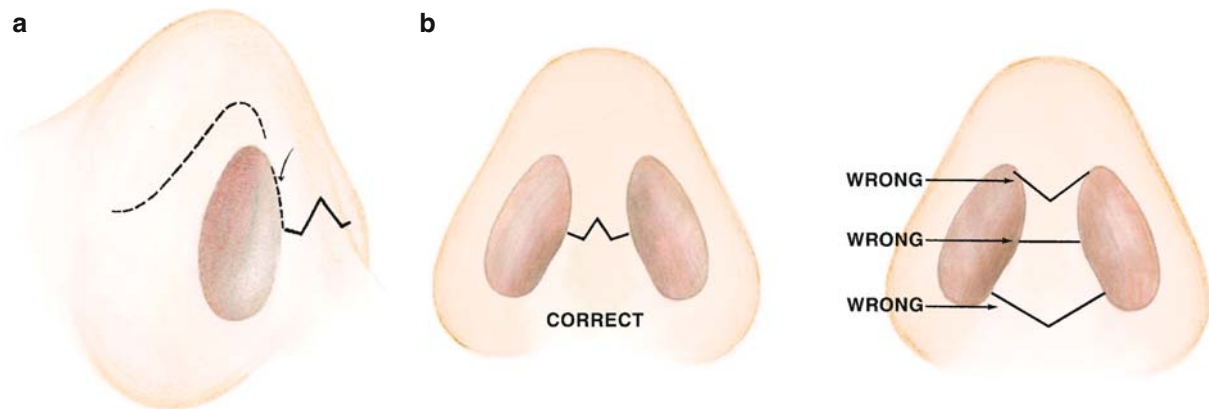


Fig. 2.3 (a–d) Open approach: incisions **DVD** (e, f) columellar to tip exposure **DVD** (g, h) bidirectional exposure **DVD**

Septal Exposure and Extramucosal Tunnels

Most surgeons think of exposure as elevating the skin envelope off the underlying structures. In reality, one must elevate the skin above and the mucosa below the osseocartilaginous vault (extramucosal tunnels) before doing the dorsal reduction.

Septal Exposure

There are two basic methods of septal exposure – the classical transfixion approach and the top-down bidirectional approach.

The Transfixion Approach. The caudal septum is exposed by retraction of the nostril rim and columellar to the left side using two wide double hooks (Fig. 2.7a, b). A vertical full-length transfixion incision is made 2–3 mm back from the caudal border on the right side. Using the angled Converse scissors, the mucosa is elevated and the subperichondrial space is entered. The lining is cross-hatch with a #15 blade and then scraped through to the cartilage using the dental amalgam [14]. Once the perichondrium is elevated, the dissection continues posteriorly over the cartilage and onto the ethmoid and vomer bones using a Cottle elevator. Inferiorly, the dissection is blocked at the junction of the cartilage and premaxilla due to the joint fascia where perichondrium and periosteum fuse. For most cases, this degree of exposure via an “anterior tunnel” is sufficient. However, in complex cases, it is necessary to create an “inferior tunnel” for complete access to the premaxilla to correct inferior bony septal deflections (Chapter 6).

The Bidirectional Top-Down Approach. With downward traction on the alar cartilages, the anterior septal angle area is exposed and one can easily elevate the septal mucosa. Additional exposure can be gained by splitting the upper lateral cartilages (ULC) off the cartilaginous dorsum or splitting the alar cartilages in the midline (Fig. 2.7c, d). In secondary cases, this area can be heavily scarred and thus a clean dissection upward from the transfixion incision allows a bidirectional exposure.

Which dissection method is preferred? In reality, the surgeon can use either one or both. I start with a transfixion incision and then split off the ULCs via the extramucosal tunnels. Following the dorsal reduction, I always have a combined bidirectional exposure which facilitates any septal surgery while preserving the tip cartilage relationships.

Extramucosal Tunnels

The purpose of extramucosal tunnels is to drop the lining mucosa away from the dorsum allowing the dorsal hump to be modified without disruption or scarring of the underlying mucosa (Fig. 2.7e). Once the septum has been exposed then additional local anesthesia is injected beneath the vault of the dorsum. The round end of the Cottle elevator is passed beneath the dorsum and then reflected downward on the septum. If a large hump is to be removed, then the mucosa is dissected off the under surface of the upper lateral cartilages. Later in the operation after the cephalic lateral crura has been resected, a second confirmatory dissection of the extramucosal tunnels can be done under direct vision.

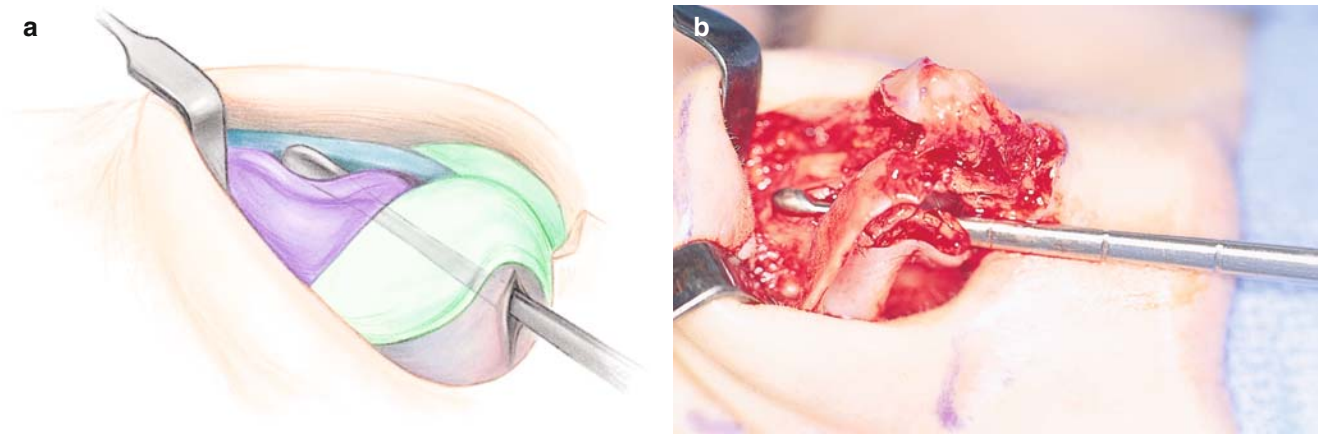


Fig. 2.4 (a, b) Septal exposure: transfixion/bidirectional DVD

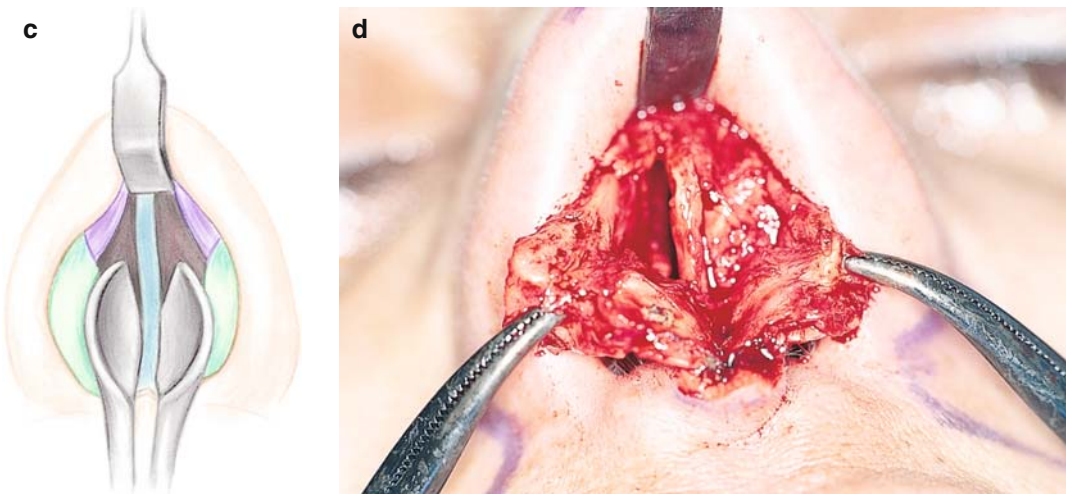


Fig. 2.4 (c, d) Septal exposure: tip split DVD

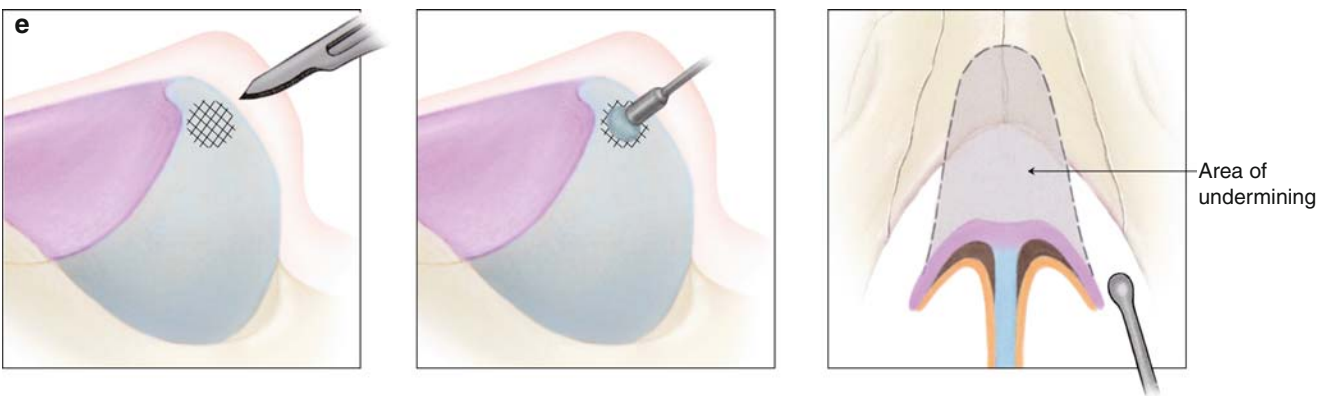


Fig. 2.4 (e) Extramucosal tunnels DVD

Tip Analysis and Symmetrical Rim Strips

Tip Analysis. With exposure completed, it is important to take a “surgical time out” and review the operative plan based on the newly revealed nasal anatomy, especially the alar cartilages (Fig. 2.5a–c). One should reconcile the planned tip surgery with the actual crural configuration, especially the domes and lateral crura. Sometimes, one will encounter unexpected anatomical variations including marked domal asymmetry (solution: a concealer graft of excised alar cartilage) or significant concavity of the lateral crura (solution: a lateral crural fold rather than excision). Also, the tip cartilages may be flimsy (preserve more than 6 mm) or thicker (more sutures may be required). Also, one should reassess the dorsum and caudal septum/anterior nasal spine (ANS). At this point, the surgeon should have an idea as to the degree of septal deviation and the amount of cartilage available for harvest.

Symmetrical Rim Strips. Attention is then directed toward resection of the cephalic portion of the alar cartilages. A portion of the cephalic lateral crura is excised in virtually all cases to reduce the volume of the nasal tip and to increase the malleability of the cartilage for shaping with sutures (Fig. 2.5d–f). In addition, the excision causes significant changes in the convexity of the lateral crura. The line of incision is marked on the alar cartilage using a caliper and marking pen. A 6 mm strip of cephalic lateral crura is left as this width facilitates insertion of sutures and retains sufficient support for the rim while minimizing any alar retraction. However, three points are important in drawing the incision line: (1) the initial 6 mm width is drawn at the widest point of the lateral crura, (2) medially, the line is tapered to preserve the natural width of the domal notch, and (3) laterally, the line follows the caudal border of the lateral crura preserving a 6 mm width. Once the line is drawn, the underlying mucosal surface of the alar cartilage is injected with local anesthesia to facilitate dissection. The cartilage is then held with forceps and a #15 blade is used to incise the lateral crura along the marked line. The actual excision of the cartilage is usually done from the domal notch area laterally. The excision follows the scroll junction with the upper lateral cartilages cephalically. Every effort is made to remove the cartilage intact as it is often used for add-on grafts.

One of the advantages of doing the excision at this point in the operative sequence is that it improves visualization of dorsal reduction. One can easily elevate the mucosa over the septal angle by dissecting upward from the exposed caudal septum thus having a bidirectional exposure. Then, the Cottle elevator is inserted longitudinally beneath the dorsum making sure that the extramucosal tunnels are adequate.

PRINCIPLES

- Volume reduction of the tip is achieved by excising the lateral crura.
- Excising the lateral crura creates symmetrical rim strips which will be sutured.
- Keep a 6 mm wide rim strip for support and suturing.
- It is rarely necessary to narrow the domal notch area.
- Follow the caudal border of the lateral crura, tapering your excision at either end.

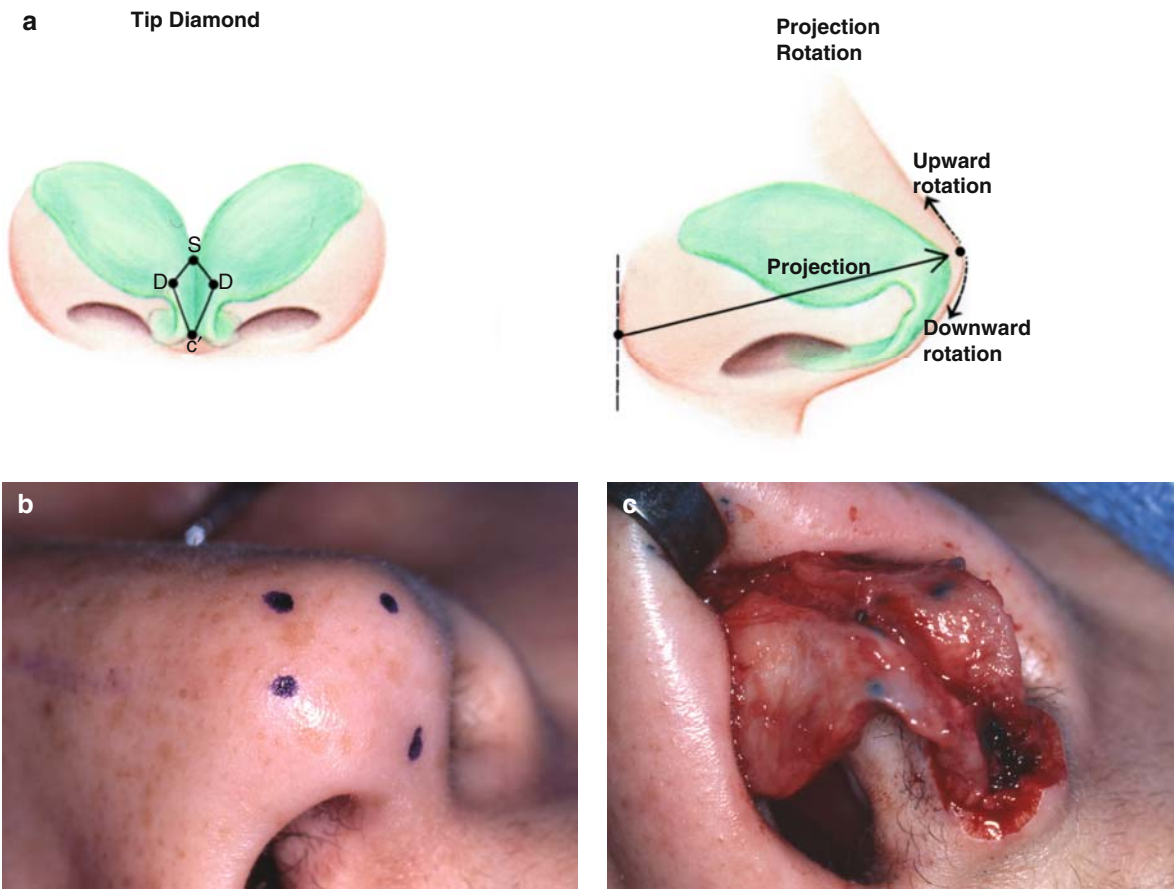


Fig. 2.5 (a–c) Tip analysis **DVD**

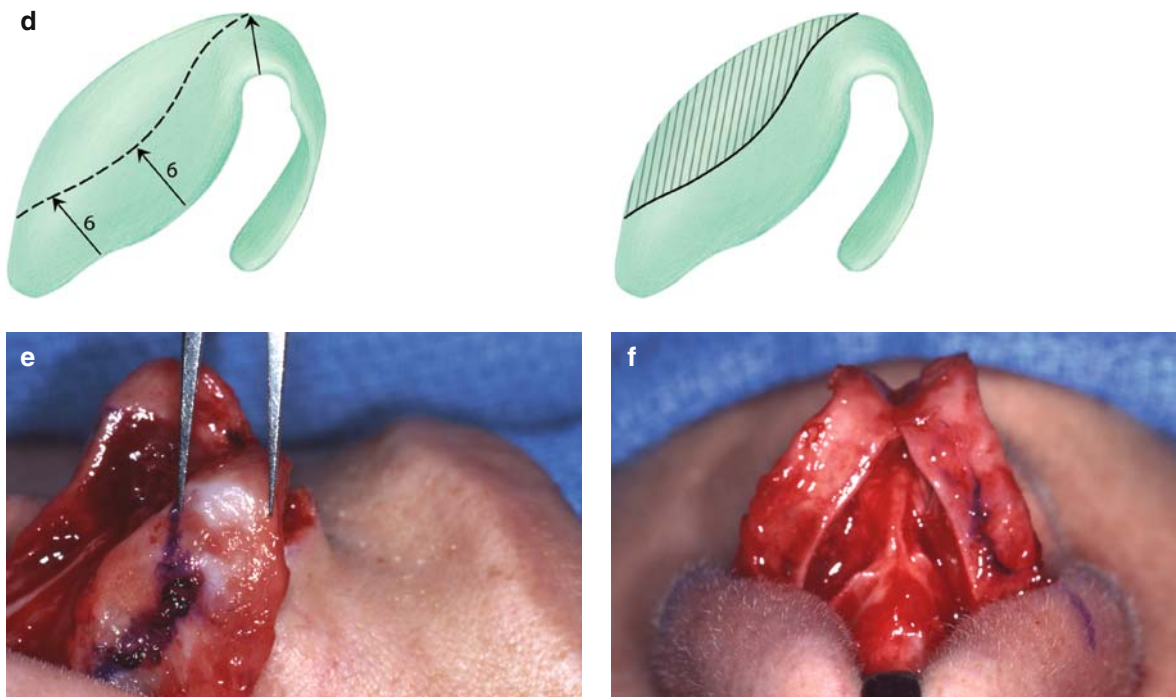


Fig. 2.5 (d–f) Symmetrical rim strips **DVD**

Dorsal Modification

Preoperatively, decisions must be made as to dorsal height (reduction, augmentation, or preservation), width (narrower, wider, or asymmetric correction) and length (shorter or longer).

Incremental Dorsal Reduction. The most common selection is dorsal reduction which is done incrementally using rasps for the bony hump and scissors for the cartilaginous hump (Figs. 2.6 and 2.7). The bone is done first using puller rasps to reduce the midline and then each nasal bone individually on an angle. Once the bony dorsum matches the ideal profile line drawn on the skin preoperatively, then the cartilaginous hump is reduced. I prefer the “split hump technique” in which the cartilaginous hump is separated into three parts (septum and two upper lateral cartilages). Straight blunt tip-serrated scissors are inserted vertically into the extramucosal tunnels. Then the cartilage is cut perpendicular to the septum thus splitting the hump. The dorsal septum is reduced incrementally with the scissors. The skin is redraped and the dorsal line checked by pulling the nasal skin laterally. Any additional lowering of the septum is done in minuscule amounts with a broken off #11 blade. Next, the upper lateral cartilages are excised conservatively. One must be cautious in this excision as the simple act of retracting the skin upward can cause the upper laterals to appear higher than they really are. In general, upper lateral excision is 33–50% of the dorsal cartilage reduction (3 mm of septum, 1–1.5 mm of upper lateral). Also, the goal is different for the two excisions – excision of the dorsal septum *reduces profile height* while excision of the upper laterals *narrows dorsal width*. At this point in the operation, it is extremely important to check the cartilaginous dorsum near the anterior septal angle. Any remaining prominence is easily removed with scissors. Finally, the dorsal line is carefully checked and micro adjustments if any are made.

Why do I prefer bony vault reduction before the cartilaginous vault and why not an osteotome? In most hump reductions, the bony vault is quite thin (<1 mm) and rasping reveals the underlying cartilaginous hump that extends 8–10 mm cephalically beneath the bone. Thus, rasping is effective and conservative while an osteotome has little margin of error and a very real risk of too much excision. Removing the bone first reveals the true dimensions of the necessary cartilaginous hump removal.

PRINCIPLES

- Ninety-five percent of patients want a smaller nose which implies dorsal reduction.
- Incremental reduction using a rasp for the bony hump and scissors for a split cartilage hump excision is the most controllable and conservative method.
- Upper lateral excision (dorsal width reduction) is usually 33–50% of the dorsal septal excision (dorsal height reduction).

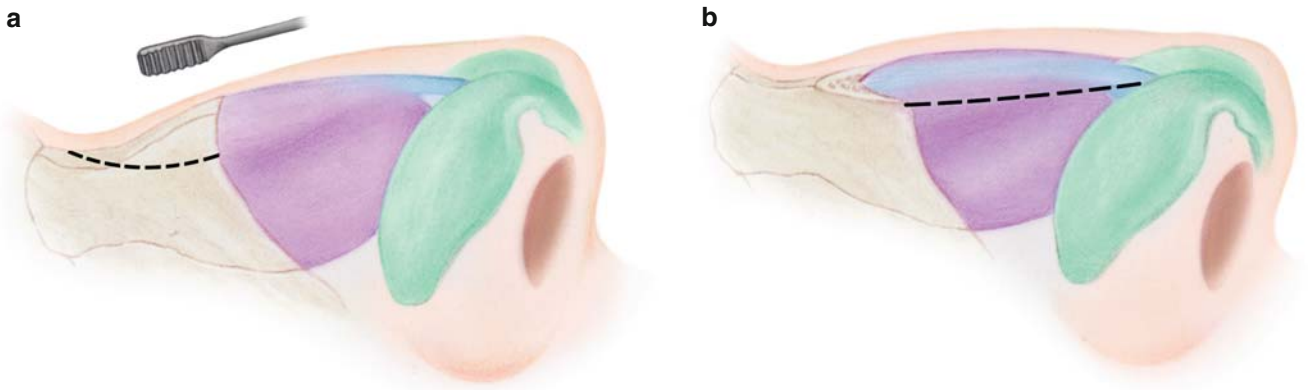


Fig. 2.6 (a, b) Bony reduction **DVD**

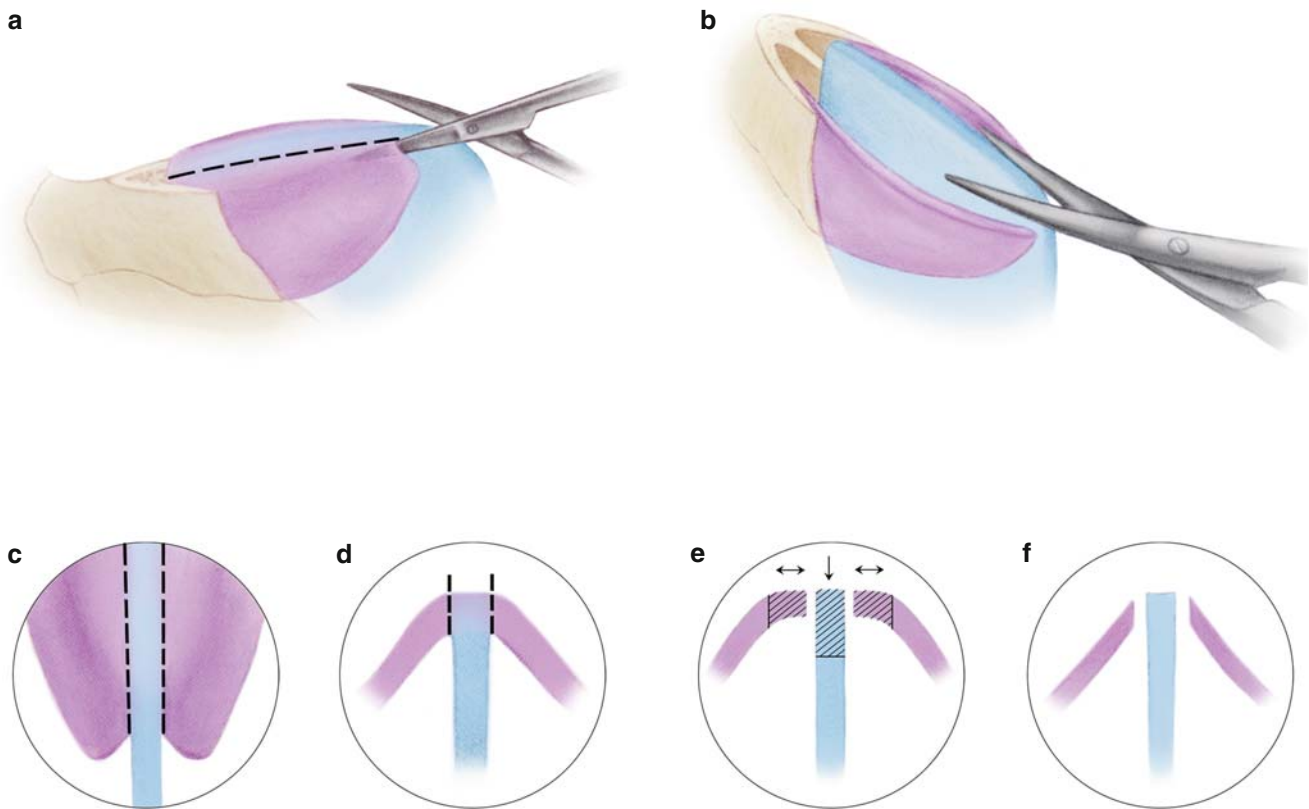


Fig. 2.7 (a-f) Cartilage reduction **DVD**

Caudal Septum and Anterior Nasal Spine

Resection. Modification of this area should be done conservatively. Preoperative assessment, both visual and palpable, in repose and on smiling is essential. Although the region can be approached through a “tip split” of the alar cartilages, greater control and flexibility is possible through the transfixion incision. Three changes are considered: (1) rotating the tip by resecting the upper half, (2) shortening the nose by resecting the lower half, and (3) altering the columellar labial segment by contouring or resecting the anterior nasal spine (Fig. 2.8). Minor changes usually consist of cartilage only resections (2–3 mm) cephalically angled for rotation or alternatively a full-length parallel resection for shortening which maintains the double break. Moderate changes tend to be slightly wider (3–5 mm), but rarely include the overlying mucosa bilaterally. For maximum change, resections can be wider and may include a portion of the mucosa. In the vast majority of the cases, one should avoid excising the membranous septum. The anterior nasal spine can be either reduced (excising its prominence while maintaining its contour) or resected to deliberately change the contour of the columella labial segment.

Grafting. Augmenting the columellar base is usually done in the form of a columellar strut to push down the columella inclination or small “plumping” grafts placed beneath the columella labial segment. Only in severe secondary cases or certain ethnic groups would diced cartilage grafts be placed in a subperiosteal transverse position across the pyriform aperture.

Caudal Septal Relocation. Correction of the deviated caudal septum is most easily achieved by relocation (Fig. 2.9). The caudal septum is freed from its bony/fibrous attachments, brought to the midline, and then sutured to the ANS. This method works extremely well if one respects three factors: (1) the caudal septum must be completely released and totally mobile, (2) fixation to the ANS must be rigid, and (3) the structural integrity of the caudal septum must not be compromised by incisions or excisions. The cartilaginous caudal septum is freed from ANS and a hole is drilled through the ANS. A 4–0 polydioxanone suture (PDS) is placed through the ANS from the nondeviated side, then through the septum, and looped on itself. The knot is then tied on the nondeviated side of the ANS. When completed, the caudal septum is rigidly fixed on the nondeviated side of the ANS midline.

PRINCIPLES

- Conservative excision of the caudal septum allows tip rotation and shortening of a long nose with a dependent tip.
- Avoid excision of the membranous septum as it often leads to disastrous upward rotation and shortening.
- Relocation of the deviated caudal septum is often necessary for both functional and aesthetic reasons.
- Caudal septal relocation is easily mastered. One should not do incisions of the caudal septum as it will weaken it.

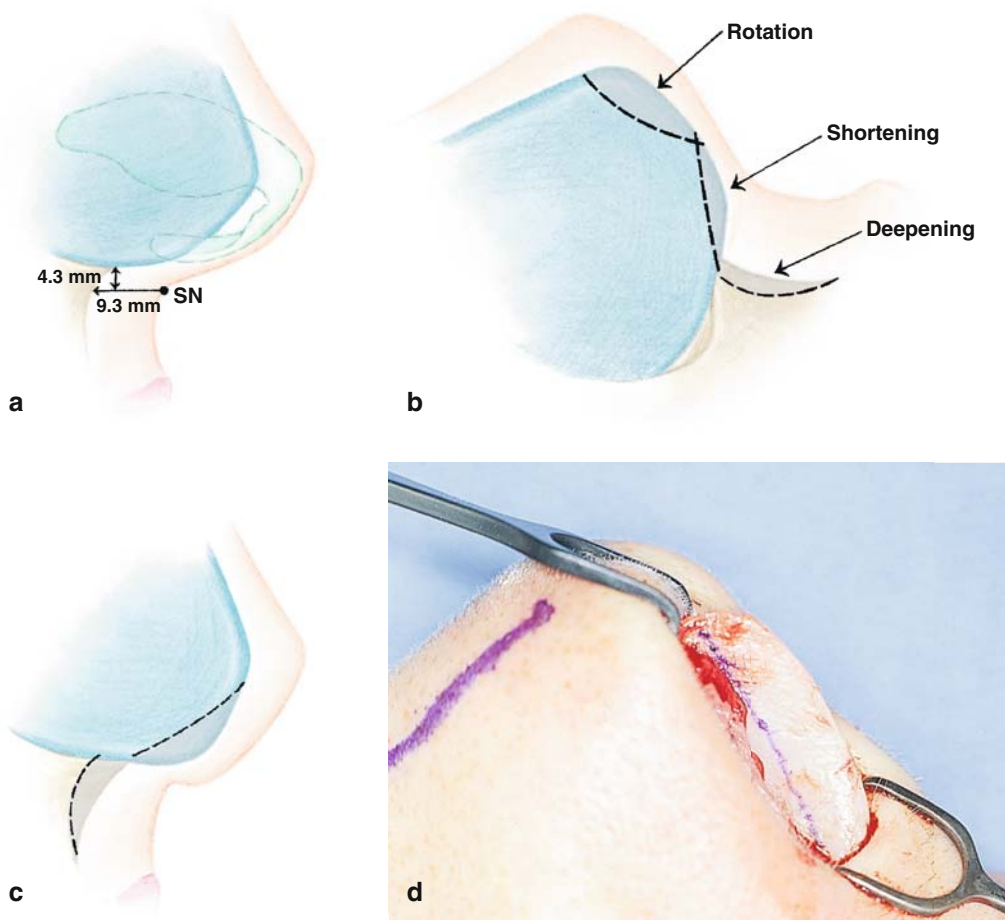


Fig. 2.8 (a-d) Caudal septal resection **DVD**

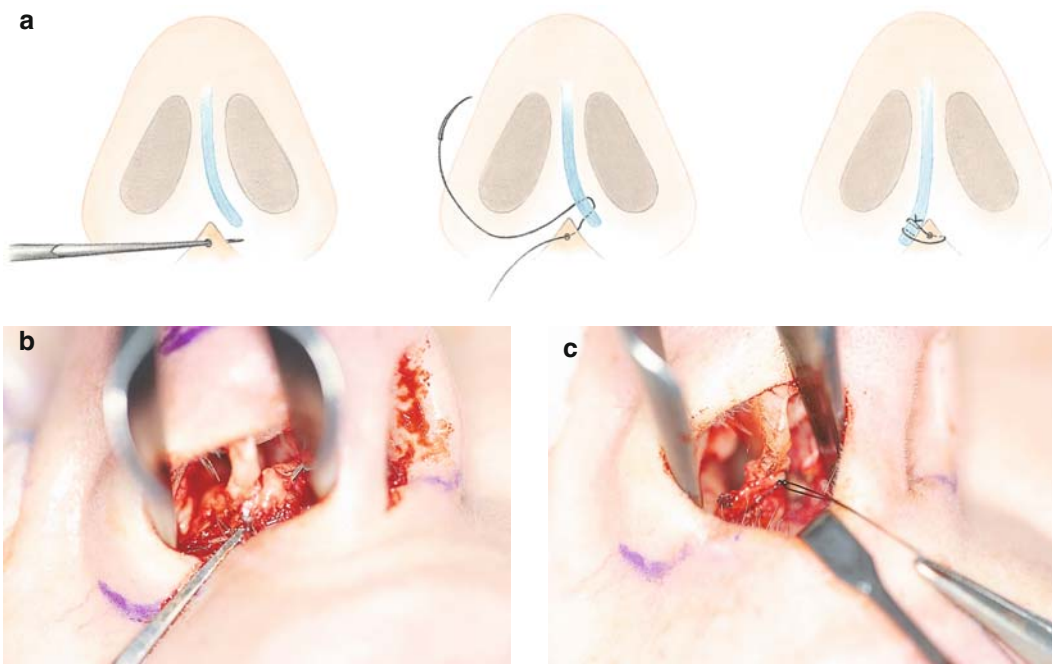


Fig. 2.9 (a-c) Caudal septal relocation **DVD**

Septal Harvest and Septoplasty

Once the desired nasal profile is established, septal correction and harvesting can be done safely without compromising septal support or risking a septal disruption. In a septal harvest procedure, one tends to take as much cartilage as required while maintaining the essential 10 mm L-shape strut (Fig. 2.10). Common variations include: (1) the lower half of cartilage for a columella strut and/or spreader grafts, (2) the available quadrilateral cartilage for multiple grafts, and (3) extensive cartilage and bone en bloc especially in Asian rhinoplasty. In all practical aspects, a septal harvest is the equivalent of a septoplasty of the septal body.

Definitive Septal Exposure. At this point in the operation, it is often wise to inspect the internal nose and reinject the septum with local anesthesia for hydrodissection. Elevation of the septal mucosal lining is usually quite easy as one has a *bidirectional approach* – top down from the dorsal resection and straight back from the transfixion incision. The dissection planes are already defined from creation of the extra mucosal tunnels. The mucosa is elevated from caudal to cephalic over the upper portion of the cartilage using the round sharp end of a Cottle elevator. Then, a vertical sweep is done back over the perpendicular plate of ethmoid and downward onto the vomer. The inferior mucosa is elevated from the posterior vomer forward which allows easier separation of the fused perichondrial/periosteal fibers. In significant deviations, it is always best to start on the easier concave side and get a feel for the tissues before doing the more challenging convex side.

Septal Harvest. Once satisfied with the exposure, the quadrilateral cartilage can be harvested which simultaneously corrects any septal body deviation. With the mucosa reflected laterally, cuts are made parallel to the dorsal and caudal portions of the desired L-shape strut. The caudal cut is extended down to the cartilaginous vomerine junction while paralleling the caudal septal border, thus preserving a 10 mm strut. The dorsal cut is easily completed under direct vision from the dorsal approach while preserving a 10 mm strut. Then the septal body is dissected out of the vomerine groove as far back as possible using the round sharp end of the Cottle elevator. One separates the cartilage from the bone vertically along the cartilage's junction with perpendicular plate of ethmoid. The “extension” of the cartilaginous septum is usually removed with the body of the septum. I do not use a septal mucosal suture to approximate the mucosal space, but rather rely on sutured Doyle splints to compress the dead space. Note: it is rarely necessary to excise large osseocartilaginous portions of the septum which increases the risk of septal collapse.

PRINCIPLES

- A 10 mm L-shaped septal strut is always maintained.
- A septal harvest implies excision of quadrilateral cartilage (no bone) and is also an effective septoplasty for body deviations.
- One must be able to do a caudal septal relocation.

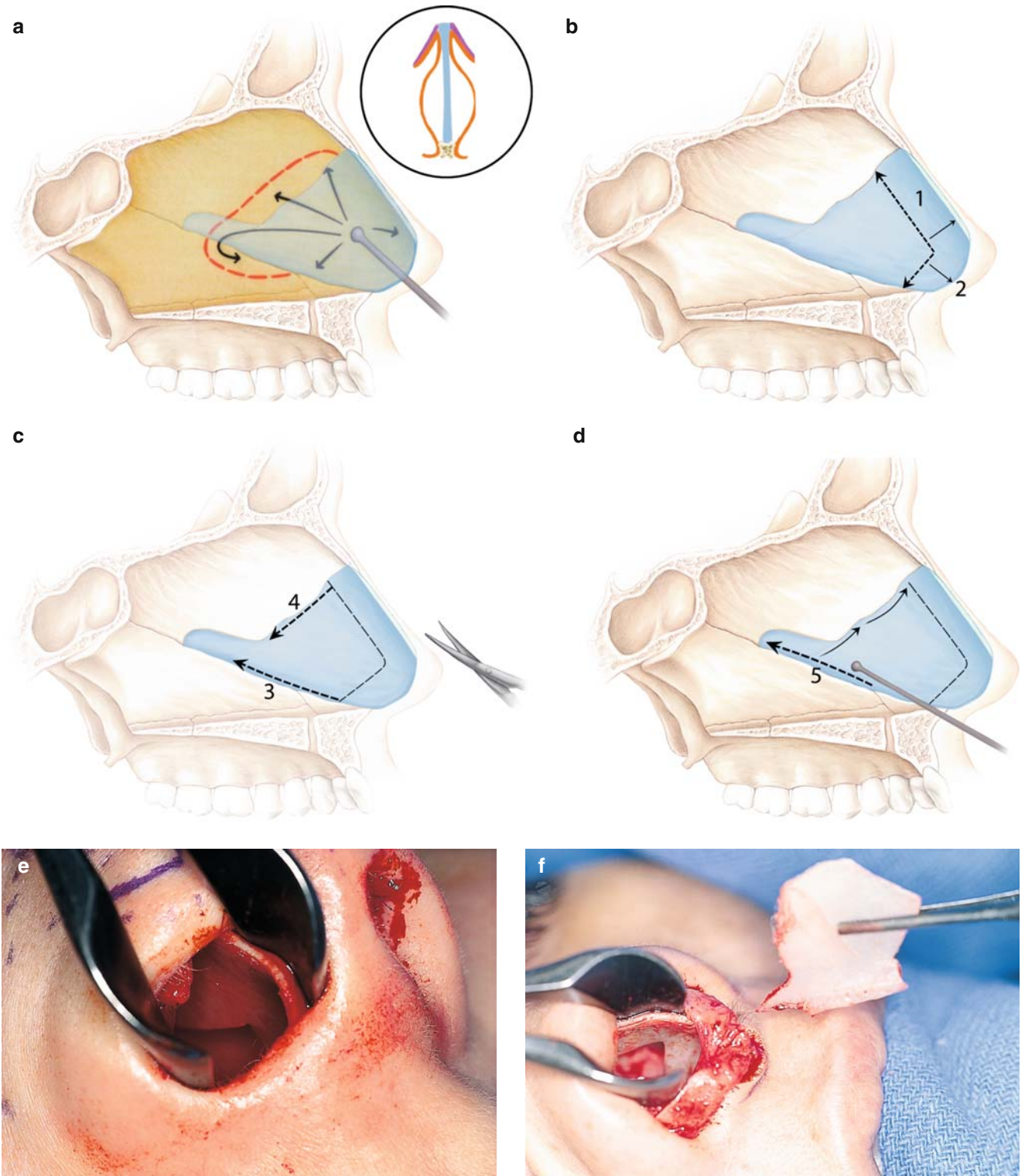



Fig. 2.10 (a–d) Septal harvest, (e) transfixion approach, (f) dorsal approach 

Osteotomies

Types of Osteotomies. The purpose of lateral osteotomies is to narrow the base bony width (x-x) of the nose as measured at its widest point; not merely to close the open dorsal roof. The two most common methods are the low-to-high and low-to-low osteotomies which differ in their direction, degree of bony fracture, and movement. The *low-to-high osteotomy* begins at the pyriform aperture on the nasal process of maxilla and passes tangentially across it to the nasal bone suture line at the level of the medial canthus (Fig. 2.11a, b). Next, digital pressure on the lateral wall results in a greenstick fracture of the transverse portion and a gentle tilt of the lateral nasal wall. In contrast, the *low-to-low osteotomy* is done in two steps (Fig. 2.11c, d). First, a transverse osteotomy is done with a 2 mm osteotome placed through a small vertical stab incision just above the medial canthus. The osteotome is gently tapped to insure a complete vertical osteotomy in the lateral nasal wall. Second, a low-to-low lateral osteotomy is done using a straight osteotome. It begins at the pyriform aperture on the nasal process of the maxilla and passes straight up the lateral wall to end at the level of the medial canthus. Digital pressure produces complete mobilization of the lateral wall and definite narrowing of the nose. The primary difference is that a low-to-high osteotomy preserves bony contact at the transverse greenstick fracture which limits movement. In contrast, the low-to-low osteotomy incorporates a complete osteotomy transversely allowing total movement of lateral nasal wall.

Osteotomy Techniques. The type of osteotomy selected is determined by the base bony width of the nose (X-point), which should be narrower than the inter-eye distance. The osteotomy site is reinjected with 0.5 cc of local anesthesia, both subcutaneously and submucosally. A small speculum is inserted vertically in the nostril and straddles the pyriform aperture. A transverse cut is made in the mucosa using a cautery. The osteotome is inserted with the guard outward to facilitate palpation. The surgeon holds the *curved* osteotome in the dominant hand and palpates the guard with the other hand. The lateral osteotomy continues to the level of the medial canthus or the base of the previous transverse osteotomy. For a low-to-high osteotomy, the osteotome is withdrawn and digital pressure is used to create a transverse greenstick fracture which produces the desired tilt. For a low-to-low osteotomy, the *straight* osteotome is rotated 90° with the blade pushing against the maxilla which forces the lateral nasal wall inward.

PRINCIPLES

- Determine the indication for osteotomies on anterior view: base bony width is the key.
- Determine the method of osteotomy by the amount of movement required: tilt (low-to-high) or complete lateral wall narrowing (low-to-low).
- Although I prefer a continuous internal osteotomy, other surgeons prefer a percutaneous method – use whichever method you are comfortable with.

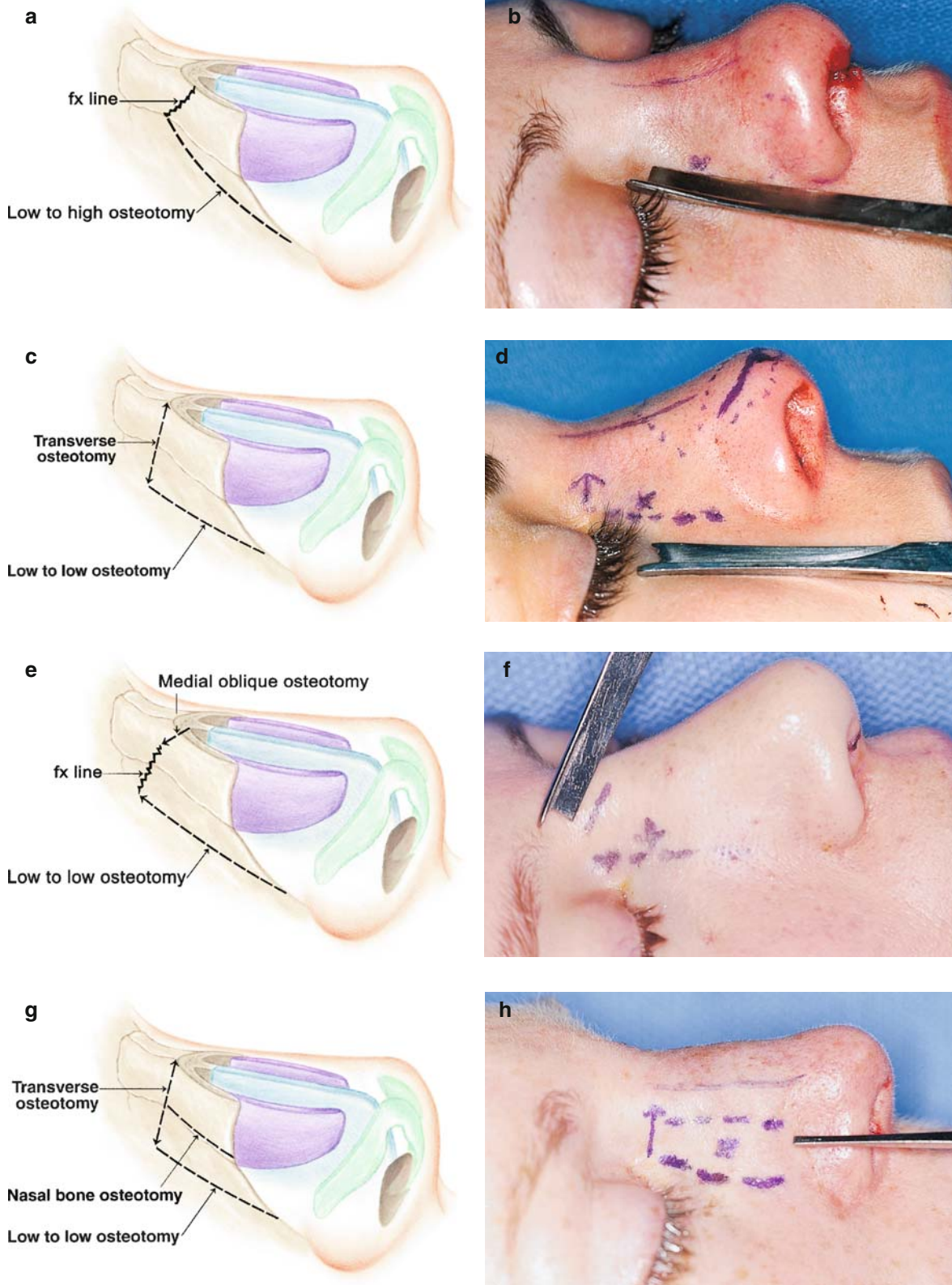


Fig. 2.11 (a, b) Low to high **DVD** (c, d) low to low **DVD** (e, f) medial oblique, (g, h) double level

Graft Preparation and Spreader Grafts

Graft Preparation. Following the osteotomies, the surgeon prepares the grafts from available materials including excised tissue (dorsum, cephalic lateral crura), septum, concha, or fascia. I alter the graft material as little as possible preferring solid cartilage grafts to either bruised or crushed grafts as the latter risk unpredictable absorption. At this point in the operation, one should reconcile which grafts are necessary with the available graft material and set priorities. In most cases, the columellar strut is the critical structural graft followed by alar rim grafts and then spreader grafts. Exceptions would be when a major structural tip graft is planned (thick skin nose) or when lateral crura strut grafts are necessary (parenthesis tip). It is important to draw the various grafts on the donor material and to be certain that the most effective utilization is achieved.

Spreader Grafts. Following the osteotomies, the dorsum is reassessed as regards smoothness and final profile. Any additional rasping is done as well as minor cartilage excisions at the keystone area. Once satisfied with the dorsum, then the spreader grafts are inserted. Spreader grafts are matchstick-sized pieces of cartilage or vomerine bone that restore the normal dorsal width of the septum which has been lost during dorsal reduction (Fig. 2.12). They can correct asymmetries, prevent an inverted-V deformity, and avoid a pinched nose. Functionally, they spread the upper lateral cartilages outward while restoring the 10–15° aperture of the internal valve and maintaining an aesthetic middle vault. They are easily cut to the desired length (20–25 mm) and height (2.5–3.5 mm), while the width (0.5–3.5 mm) varies with the desired aesthetics of the middle vault. Most surgeons elevate the mucosa along the dorsal cartilaginous septum and create small pockets cephalically beneath the remaining intact dorsum. The grafts are then fixed with two #25 needles passed percutaneously through the skin. It is important that the grafts be flush with the dorsal septum, slightly proximal to the internal valve, and extend beneath the intact dorsum. The grafts are then sutured into place. Most commonly, a horizontal mattress suture of 4-0 PDS is used to fix all five structures together (upper laterals, spreader grafts, and septum). Cephalically, one can do a variety of suture techniques.

PRINCIPLES

- Carefully assess graft requirements and prioritize available material.
- Check the dorsum carefully – stretch skin laterally, palpate with a wet finger, smooth everything.
- Have a low threshold for doing spreader grafts. I have never regretted doing them, but have regretted not doing them.
- Spreader grafts are best sutured into place; otherwise they will slip out or ride up over the dorsum.

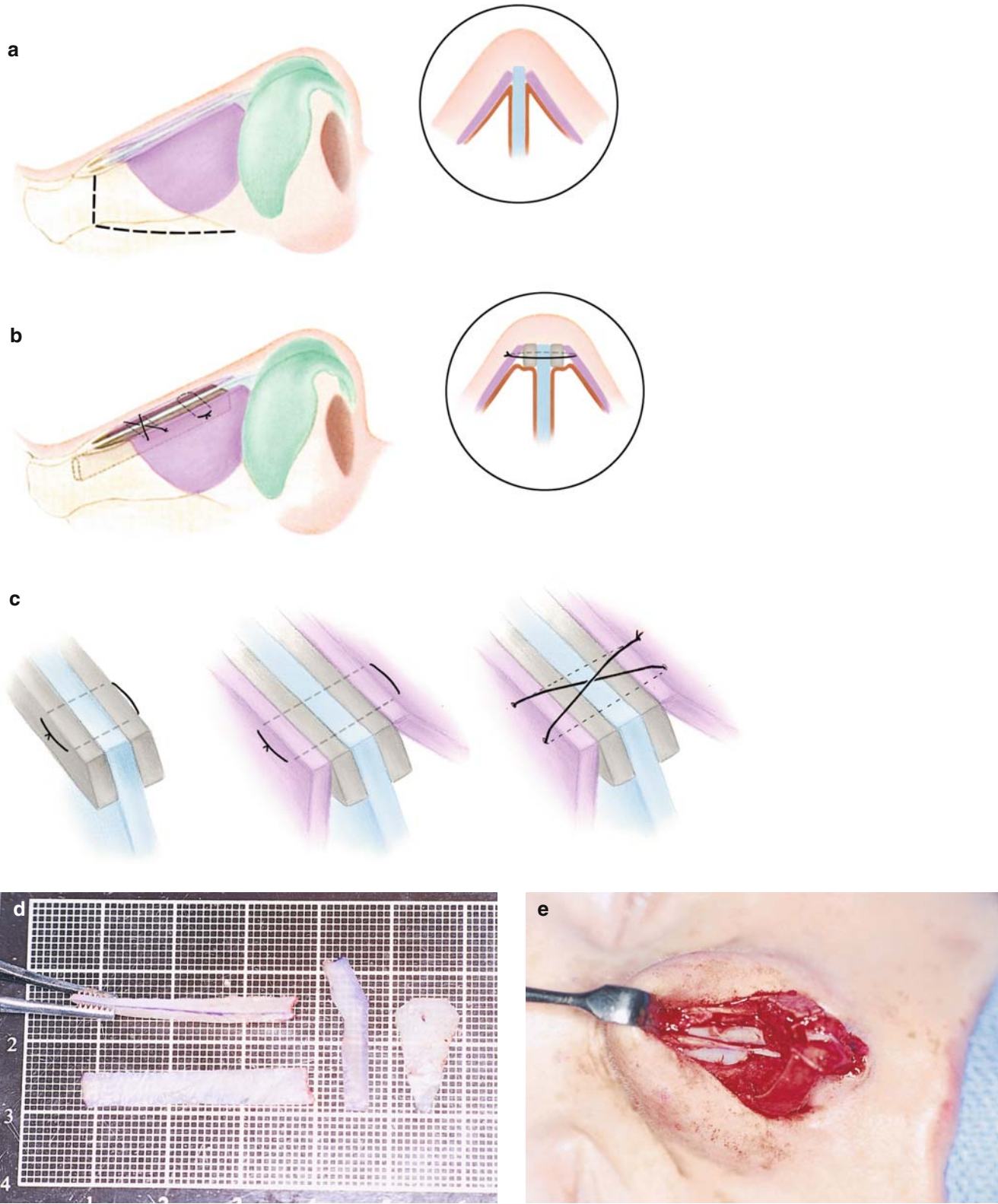


Fig. 2.12 (a-e) Spreader grafts 

Tip Surgery

After 25 years of experience, it has become obvious to me that an open tip suture technique can produce a beautiful aesthetic tip. It has flexibility, finesse, and control that are virtually impossible with other techniques (Table 2.2). Incorporation of add-on grafts of excised alar cartilage to the suture sequence has dramatically reduced the need for open structure tip grafts with their attendant problems. Thus, the open tip suture technique should be the basic tip operation mastered first by rhinoplasty surgeons. I will present the highlights of the tip suture sequence in this chapter. Note: tip suture techniques will be discussed repeatedly throughout the text. Consider this portion just as an introduction to the technique with greater detail available in Chapters 4 and 8. The importance of viewing the DVD clips of individual sutures can not be over emphasized. At this point in the operation, the ideal dorsal profile line has been established and symmetrical rim strips produced. It is now time to create an aesthetic tip.


1) Columellar Strut and Suture

The columellar strut and suture provide three important benefits: tip stability, tip projection, and columellar shape. The strut fosters verticality and projection while eliminating plunging of the tip. Suturing the alars to the strut creates a unified tip complex and improves symmetry.

The three steps are shaping, insertion, and suture fixation of the strut (Fig. 2.13). The columellar strut is usually cut 20 mm long, 2.5 mm wide, and 1.5 mm thick. The ideal graft material is from the vomerine septal cartilage because of its rigidity and thickness. The graft is easily shaped to the desired dimensions using a #15 blade. The midpoint is marked with a pen. The actual shape of the graft can vary widely depending upon the need, including correction of a retrusive columellar labial angle. A recipient pocket is easily made between the alar cartilages and the strut inserted down to its midpoint. Then the alars are elevated upward and rotated 90° medially. They are fixed individually to the strut with a #25 needle placed high on the middle crura just below the domes. This needle placement tends to verticalize the tip. Symmetry is important as regards domal location and caudal relationships. A vertical suture of 5-0 PDS is placed across the columellar which sandwiches the strut between the middle crura. Although some surgeons widely separate the alar cartilages for either septal exposure or total mobilization, this maneuver necessitates a total rebuilding of the crural relationship rather than a simple adjustment.

PRINCIPLES

- All suture materials are absorbable to minimize infection and colored (violet) to increase visibility.
- One of the biggest advantages of the columellar strut is that it insures that the columellar is straight and renders it somewhat independent of the caudal septum
- Learn to recognize the *domal notch* – it is the key reference point for locating the domal creation suture.
- The tip position rotation suture is the *most powerful* of all the tip sutures and must never be tied too tight! Too loose is much better than too tight.
- Whenever possible use excised alar cartilage for add-on grafts.
- These grafts provide subtle tip refinement and accentuate changes produced by suturing.

Table 2.2 Open tip suture technique 

Step	Surgical technique	Effect	Frequency
Step #1	Symmetrical rim strips	Decrease volume	99%
	Cephalic lateral crura excision	More suturable	Leave 6 mm
Step #2	Columellar strut with strut suture	Increases projection	99%
		Prevents drooping	
Step #3	Domal creation suture R & L	Increases definition	95%
Step #4	Interdomal suture	Decreases tip width	90%
		Creates tip diamond	
Step #5	Domal equalization suture	Increase symmetry	75%
Step #6	Lateral crural convexity suture	Decreases convexity	20%
		of lateral crura	
Step #7	Tip position suture	Increase projection	75%
		Increase rotation	
Step #8	Add-on grafts	Increases definition	40%
		Increase projections	
Step #9	Alar rim grafts	Supports alar rims	10–15%

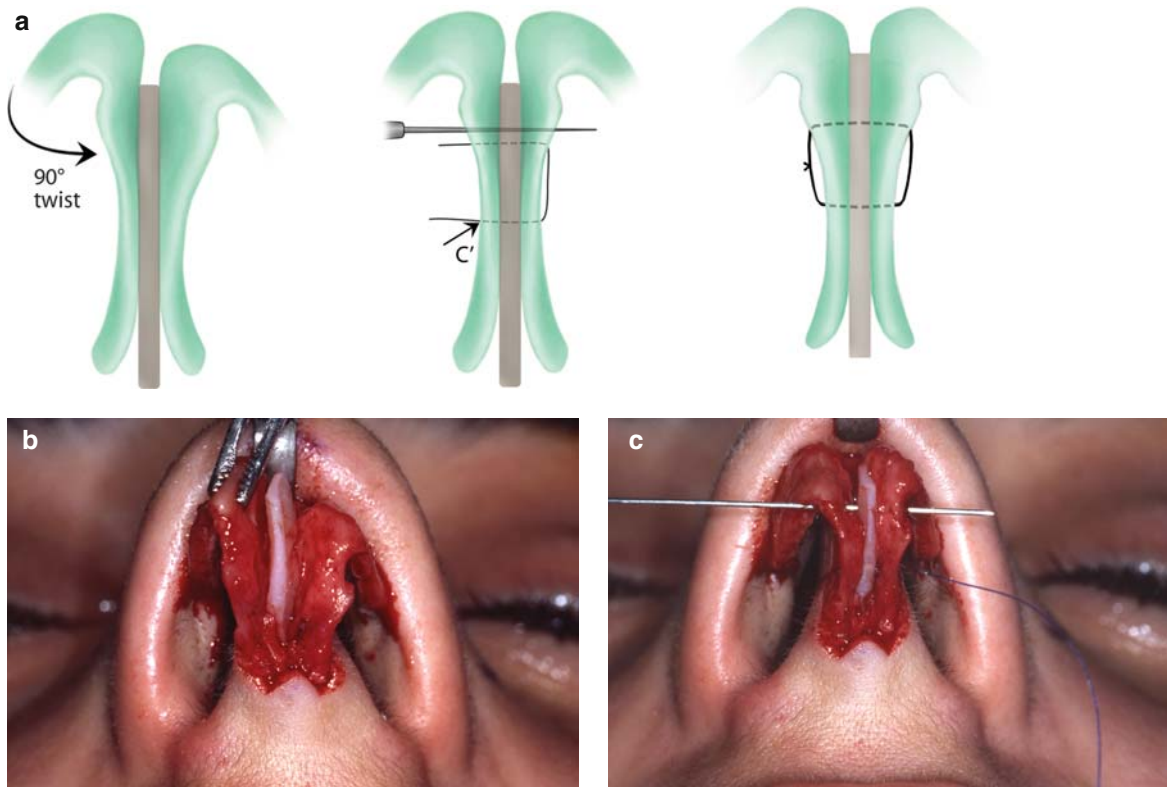



Fig. 2.13 (a–c) Columellar strut and suture 

2) Domal Creation Suture

The domal creation suture produces tip definition by creating the ideal domal anatomy, even from flat or concave cartilages. Essentially, one inserts a horizontal mattress suture across the domal segment at the domal notch and cinches it down to create a convex domal segment next to a concave lateral crura (Fig. 2.14). This anatomical configuration produces the most attractive tip once the skin is redraped.

Although conceptually simple, the surgeon must become facile with this suture. The domal notch is determined and gently squeezed with an Adson-Brown forceps to determine the desired amount of convexity. The new dome defining point is marked.

Then a horizontal mattress suture is placed from medial to lateral with the knot tied medially. The tension is gradually tightened until the desired domal convexity is achieved. Although one focuses on the domal convexity, the reality is a gradually increasing domal convexity next to a gradually increasing lateral crura concavity. The following five suture errors are to be avoided: (1) too tight can result in a sharp point under thin skin, (2) too loose fails to achieve the desired definition, (3) too medial a placement snubs off the tip, (4) too lateral a placement makes the infralobule lengthy, and (5) do not try to modify the entire lateral crura, just the area comprising the dome. Unlike incision and excision techniques, which weaken the rim strip and often lead to bossa, the domal suture is initially reversible and can be replaced several times depending upon the rigidity of the cartilage. In contrast to tip grafts with their disadvantages, tip sutures achieve definition without visibility, cartilage atrophy, or thinning of the skin.

3) Interdomal Suture

The interdomal suture controls tip width both at the domes and in the infralobule. It is a simple vertical suture that begins on one crura adjacent to the domal creation suture, exits above the crural suture, then enters the opposite crura at the same level, and exits adjacent to the domal creation suture (Fig. 2.15). The knot is gradually tightened until the ideal width is achieved. The simplicity of inserting this stitch is due to its place in the tip suturing sequence. Since the columellar strut suture and domal creation sutures are already in place, the location of the interdomal suture is virtually predetermined. The suture enters just below the domal creation knot on the left and exits just above the sutured middle crura. Then the suture enters the right crura directly across on the middle crura and exits just below the domal creation knot. The only decisions are how far back from the caudal border to insert the suture and how tight to tie the knot. In general, the suture is placed 2–3 mm back from the caudal border of the crura. If placed too close to the caudal edge then excessive narrowing of the columellar occurs. The suture is gradually tightened to reduce the interdomal width not to create a single pointy tip. Remember the “tip diamond” concept. Also, the columellar flares at its base, narrows at its mid point, and gradually widens in the infralobule.

4) Tip Position Suture

The tip position suture achieves both tip rotation and increases projection which in turn creates the *supratip break* that most patients desire. It is a simple transverse suture between the infralobular mucosa and the anterior dorsal septum (Fig. 2.16a–c). As the knot is tightened the tip rotates upward and projects above the dorsal line creating a supratip set off. Early on, one should do a single throw, redrape the skin, and assess its effect – be careful, over rotation is a disaster.

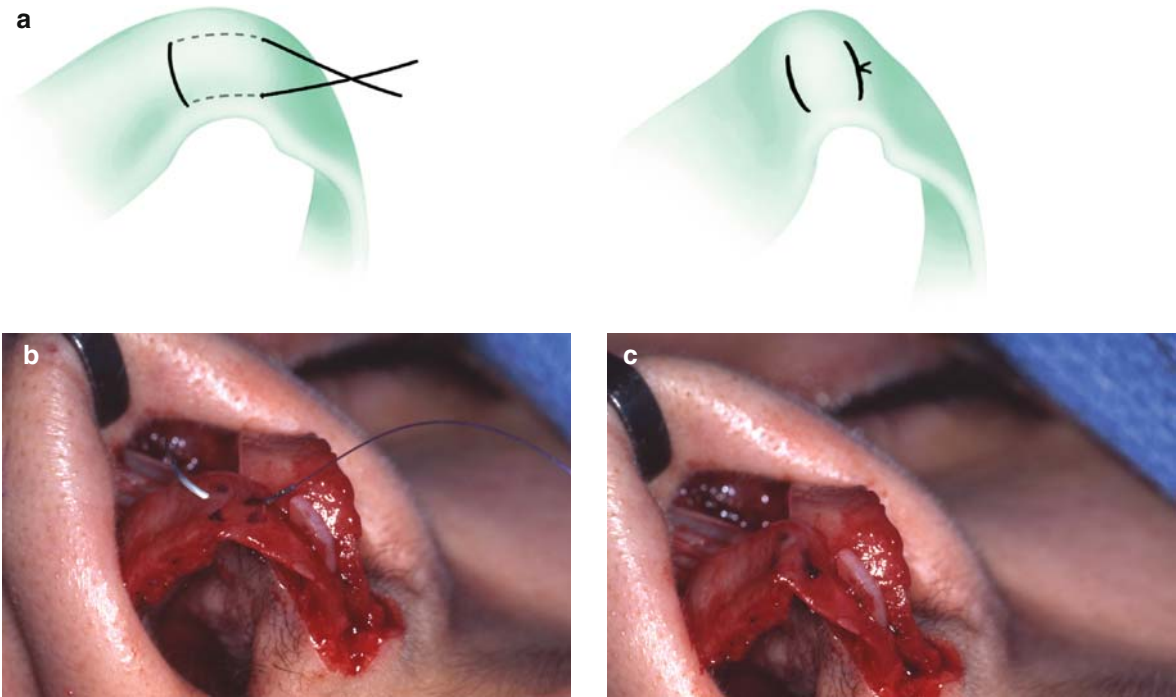


Fig. 2.14 (a-c) Domal creation suture **DVD**

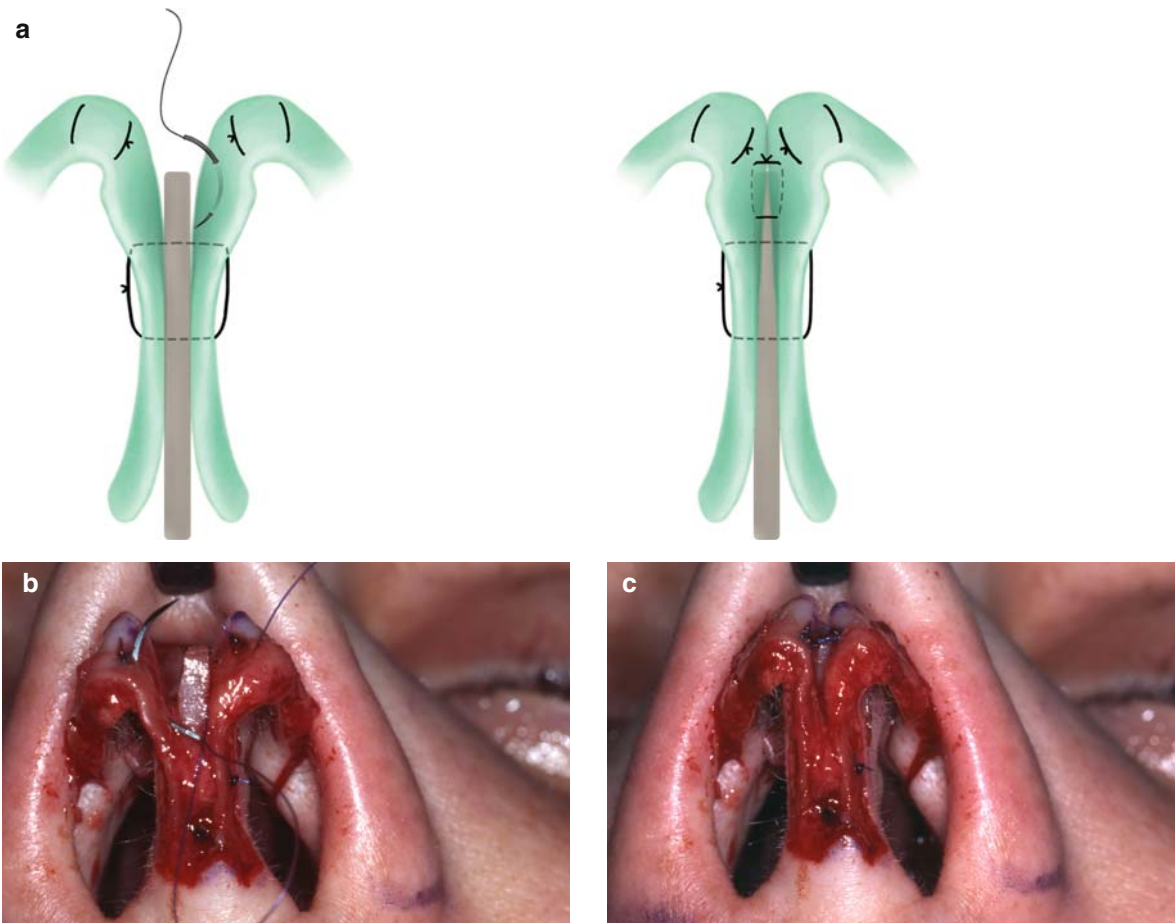


Fig. 2.15 (a-c) Interdomal suture **DVD**

The tip position suture is inserted as follows. A 4-0 PDS suture on an FS2 needle is used. The surgeon stands at the top of the table. The suture is transverse beginning with a pass through the mucosa of the infralobule with optional inclusion of the columellar strut. The next pass is through the dorsal septum about 3–4 mm back from the anterior septal angle usually avoiding the spreader grafts. In general, I will do a single throw, redrape the skin, and assess the changes before adding additional ties. It is never tied rigidly tight, but rather serves as a loop bringing the tip above the anterior septal angle. The goal is to rotate the tip slightly while giving additional support to the tip which in turn creates the desired super tip break. I find this method of suturing more effective and with less risk of columellar distortion than Gruber's columellar-septal suture. Equally, I am not a fan of the tongue-in-groove technique where the alar cartilages are rotated on either side of the caudal septum and then fixed with sutures. The problem with the latter suture is that fine-graded adjustments in rotation and projection cannot be made once the alars are sutured to the septum. In contrast, the tip position suture is inserted after the ideal tip is created and the tension can be tightened incrementally.

5) Add-On Tip Refinement Grafts

Once suturing is completed, small tip grafts can be added to provide additional refinement (Daniel, 2002, 2009). Ideally, these grafts are made from excised alar cartilage and can be placed in different locations and combinations (Fig. 2.16d–f). Initially, I used these grafts as “concealer” grafts to hide tip asymmetry or bifidity under thin skin. However, their application has been expanded to include greater infralobular curvature (infralobule position) and tip definition (transdomal position). They are truly “added on” to the final sutured tip to enhance tip refinement with minimal risk. Whenever possible, excised alar cartilage is used as it is quite pliable, easily shaped, and can be layered. These grafts have minimal risk of showing through the skin in contrast to rigid grafts of septal or conchal cartilage. The two most common locations are transdomal (Peck-type graft) and infralobular (Sheen-type graft). The *transdomal onlay* graft is placed over the domes to increase tip definition or used as a double layer to slightly increase tip projection. The grafts are sutured to the underlying alar cartilages at the graft's four corners. The *infralobular* graft is cut in a tapered Sheen “shield” style and sutured to the alar cartilages at the domal notch and midcolumellar points. Prior to suturing, the top of the graft can be raised to the edge of the cartilage or slightly above to either increase projection or accentuate caudal tip position. If the top edge is raised more than 1 mm above the cartilage then a “cap” graft must be placed behind it to provide ridge support. These grafts can be either a transdomal or a vertical wedge depending upon where tip refinement is desired. Inherently, these grafts are also concealing any asymmetries. If the grafts are too visible, the first choice is to remove them. If the grafts are absolutely essential as in an asymmetric tip with thin skin, then one can consider adding a fascia graft to provide thicker soft tissue coverage.

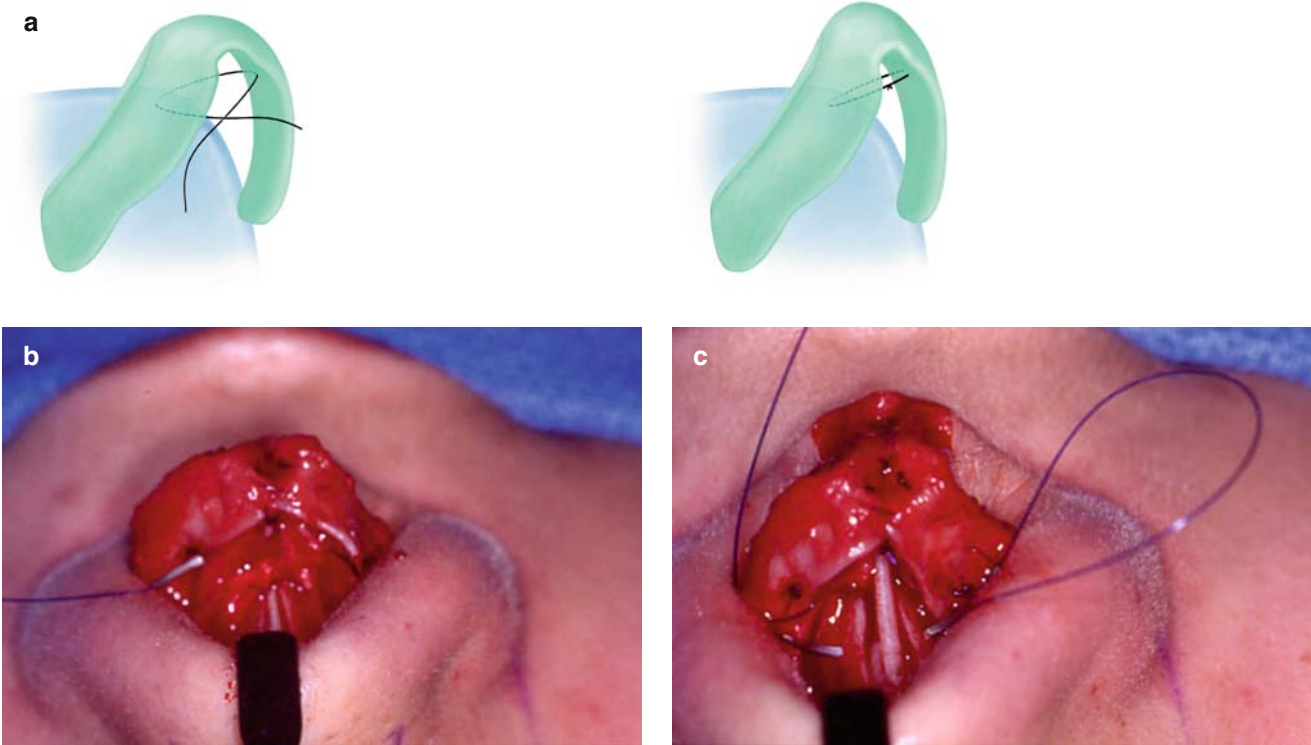


Fig. 2.16 (a-c) Tip position suture **DVD**

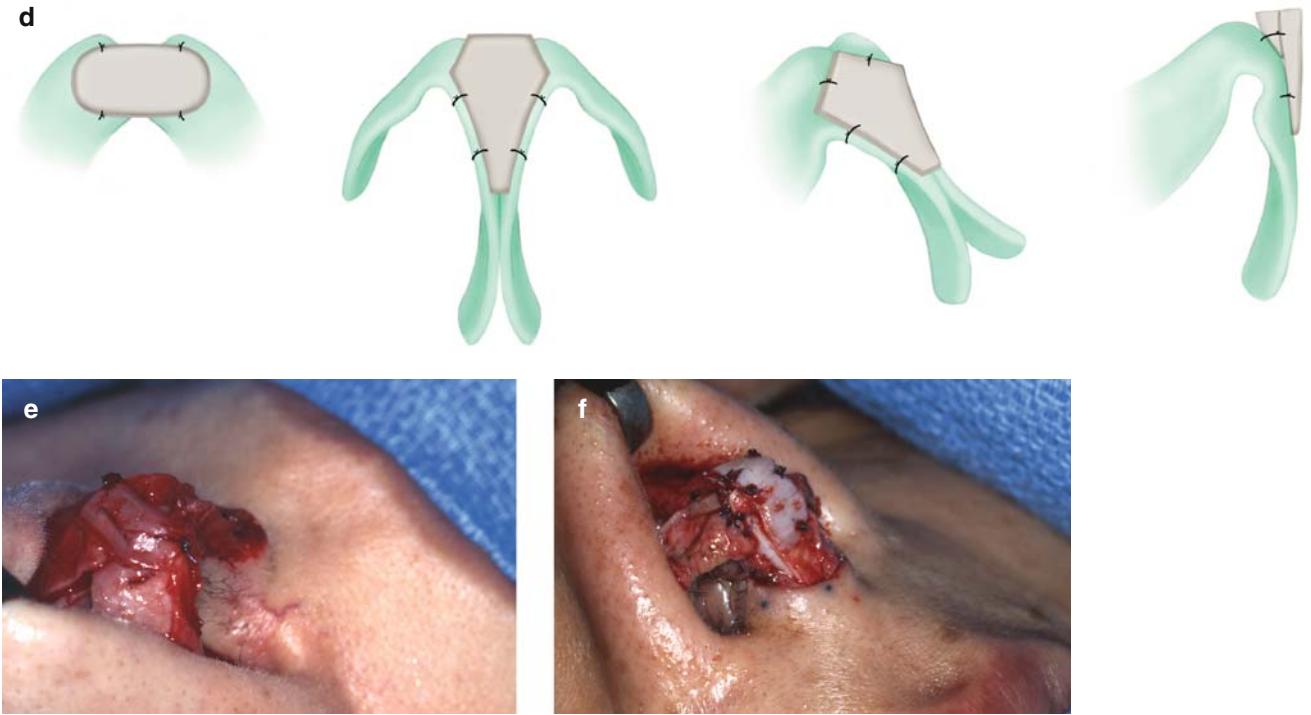


Fig. 2.16 (d-f) Add-on tip refinement grafts **DVD**

Alar Base Modification

Alar base modification should be carefully planned preoperatively, and executed very conservatively; aggressive excisions can be disastrous and virtually irreparable. The decision as to the type and amount of the excision is based upon nostril shape and sill width. The critical factor is the relationship between alar flare and alar width as regards intercanthal width. Alar width (AC-AC) is measured at the alar crease, whereas alar flare (AL-AL) is measured at the widest point of the alar, usually 3–4 mm above the crease. These two distances as well as the intercanthal width (EN-EN) are easily measured with a sliding caliper directly on the patient. The critical decision is whether alar width (AL-AL) is greater than intercanthal width (EN-EN) preoperatively or will become greater as dorsal support and tip projection are reduced intraoperatively. There are basically three surgical techniques: (1) a simple nostril sill excision to reduce nostril show, (2) an alar wedge excision to reduce nostril flare, and (3) a combined sill/wedge excision with components that can reduce flare as well as alar width.

Nostril Sill Excision. For nostril sill excisions, a 2.5–3.5 mm wide inverted trapezoid is drawn (Fig. 2.17a, b). The sides are vertical and then triangular with equal extension into the vestibule and onto the skin surface. After injection with local anesthesia, the wedge is excised. The sill/vestibule component is closed with a horizontal mattress suture of 4–0 plain catgut which everts the edges and prevents a depressed scar. The skin is closed with 6–0 nylon.

Alar Wedge Excision. For alar wedge excisions, it is important that the line of incision be placed in the alar crease; too high produces a visible scar. The line of excision is drawn using a caliper (2.5–4 mm average) with quantitative variance on the two sides to accommodate asymmetries (Fig. 2.17c, d). The base is injected with local anesthesia; a fresh #15 blade is used. With the area stabilized on a skin hook, a V-wedge excision is made without penetrating the underlying vestibular skin. Following hemostasis, the edges are closed with 6–0 nylon and the knots placed on the more dependent side.

Combined Sill/Wedge Excision. In more severe cases, a combined excision of nostril sill and alar wedge is necessary (Fig. 2.17e, f). These are complex advanced excisions which are most common in ethnic rhinoplasty cases and will be discussed later.

PRINCIPLES

- Alar base modification must be done precisely and conservatively.
- One should master isolated alar wedge and nostril sill excisions before doing combined excisions.
- Alar rim grafts are often necessary as alar base excisions accentuates alar rim notching.

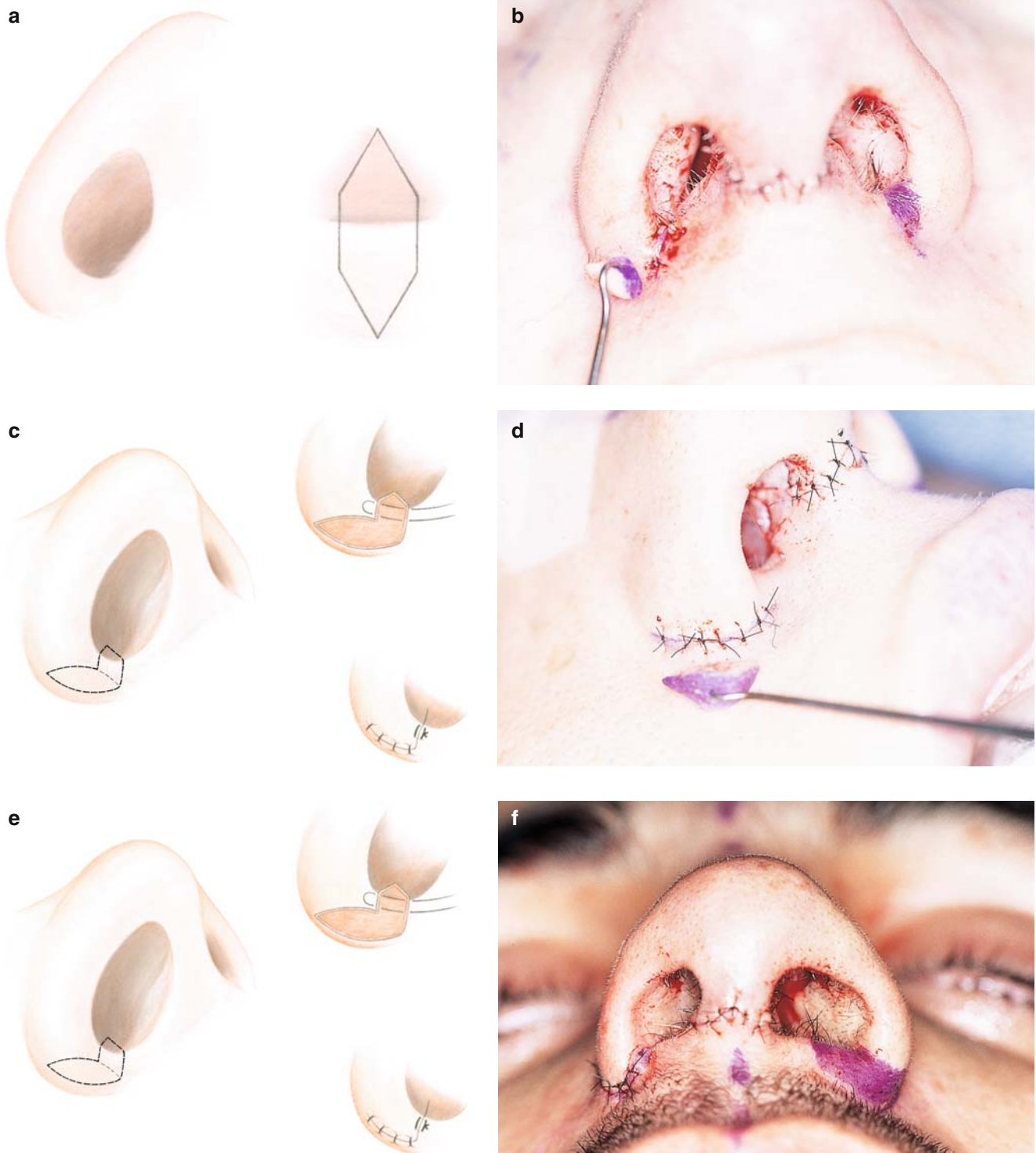


Fig. 2.17 (a, b) Nostril sill **DVD** (c, d) alar wedge **DVD** (e, f) combined sill/wedge excision **DVD**

Closure, Cast, and Post-op Management

All incisions are sutured. I begin with the transcolumellar incision: first, the midline suture at the apex of the V for alignment; second, the lateral corner sutures to insure redraping of the skin; and third, the columellar pillar sutures. Additional interrupted sutures of 6-0 nylon are added as indicated. Then the infracartilaginous incisions are closed with two sutures of 5-0 plain catgut. Rather than lining up predetermined dots, I favor two angulated sutures from lateral to dome. However, one must avoid notching the alar rim by suturing the mobile alar rim to a retracted alar cartilage. This problem can be treated by insertion of an alar rim graft. The transfixion incision is closed with 2-3 sutures of 4-0 plain catgut.

The classic nasal packing is not used. It is not necessary, and patients hate it. If septal or turbinate work was done, then Doyle splints lubricated with polysporin ointment are inserted into the nasal airways (Fig. 2.18a, b). The splints are sutured together to compress the mucosal leaflets with a single horizontal mattress suture of 4-0 nylon which is always tied on the left side. These splints minimize the risk of a septal hematoma and prevent synechiae formation. The tubes are left on the Doyle splints when major septal straightening has been done and removed in other cases to facilitate breathing. The nose is then taped with 0.5 in. wide Steri-strips which compress the skin envelope, reduce edema, and model the tip (Fig. 2.18c). The tapes are applied in the following sequence: (1) three slightly overlapping transverse tapes on the bridge from radix to supratip, (2) two longitudinal tapes placed along the edges of the bridge of the nose and then pinched together to both narrow the tip and support it, and (3) another transverse tape to compress the supratip skin. A small piece of Telfa gauze (4 × 1 cm) is placed along the dorsum which will facilitate subsequent removal of the nasal splint. The plastic polymer splint is placed in boiling water to become flexible, molded over the bony portion of the nose, and then instantly “set” by pouring ice water over it.

The surgeon immediately dictates the operative report and fills out the operative flow sheet and diagrams. The smoothness of the postoperative course is directly proportional to the amount of time spent at the preoperative visit explaining to the patient what to expect. The post-op medications are confirmed (Vicodin for pain, cephalosporin antibiotic for 5 days). The patient is reminded to clean all suture lines free of crusts – two to three times a day with hydrogen peroxide and apply polysporin ointment. At 6 days, the dressings are removed in the following sequence: (1) the external cast is rocked side to side and comes off easily because of the Telfa sheet on the dorsum, (2) Steri-strips, (3) internal splints after cutting the suture on the left side, and (4) columellar and alar sutures,

PRINCIPLES

- The ease of the postoperative course is directly related to the thoroughness of the pre-op visit.
- Eversion of the nostril sill closure is critical, thus the horizontal mattress of 4-0 plain that everts the edges.
- After the cast is removed, the nose is taped using same taping method as intraop. The patient tapes at night for 3 weeks.

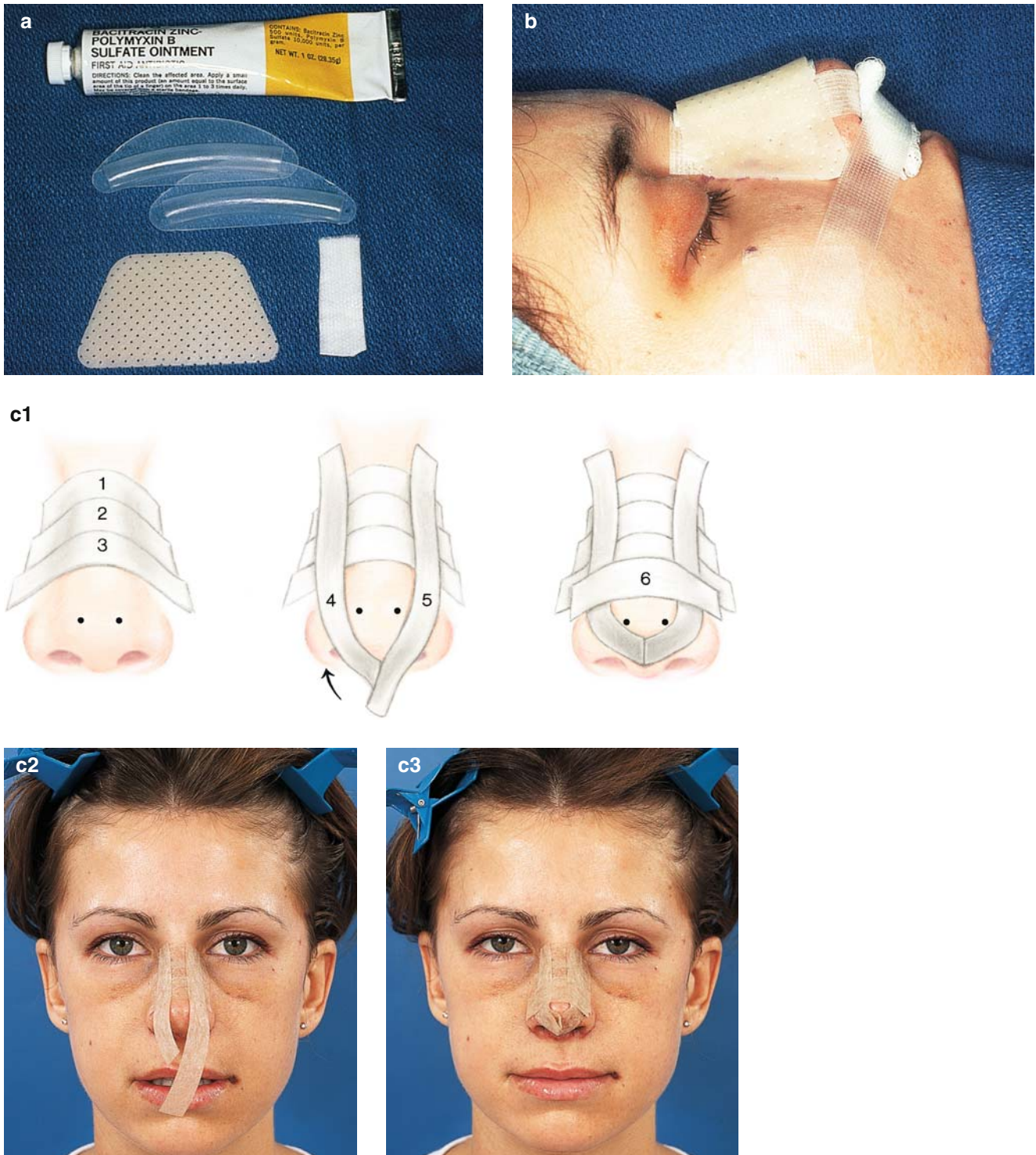


Fig. 2.18 (a, b) Dressing, (c) postoperative taping **DVD**

The Basic Rhinoplasty Operation: A 95% Solution

This fundamental rhinoplasty operation allows surgeons to achieve very good results with an excellent margin of error. It is assumed that the surgeon has basic rhinoplasty skills acquired during their residency training. Building from their own foundation, one should assimilate the various parts of this standard operation. The surgeon does not need to use every step in every nasal surgery. However, one can be sure that every step might be required in the actual case one is doing that day. One cannot avoid correcting the anatomical causes of nasal obstruction that preexist in 35% of the cosmetic cases. As the surgeon gains experience, the operation can be expanded to an ever widening variety of cases and specific techniques added. A good example is incorporation of add-on grafts to get greater tip definition in thick skin patients and the use of alar rim grafts to minimize alar retraction. Some surgeons will question various aspects of this basic operation and I will attempt to address their concerns.

Q. Originally, you thought that a basic rhinoplasty operation was impossible because of the diversity of patients and operative techniques. What is different now?

A. I have concluded that a surgeon who does less than 35 rhinoplasties a year should learn one expandable operation well, select cases that are within their comfort zone, and commit to learning surgical cause and effect by keeping meticulous records of each procedure. Over a 3-year period, the surgeon can then expand their comfort zone and case profile from Level 1 to Level 2 which will cover 95% of the primary patients seen in a normal practice.

Q. Why the open approach in all cases?

A. A rhinoplasty is much easier to do open than closed. The variety of available tip procedures is much greater and 95% of the major secondary cases are done open. Therefore, it makes sense to master the open approach. If one is comfortable with the endonasal approach and wants to use it in some cases with limited tip deformities, that approach is certainly appropriate. However, for those with the usual limited residency experience, it makes sense to concentrate on one approach and that is the expandable open approach.

Q. Are you suggesting a septal harvest on all patients?

A. Yes, I am doing a septal harvest in most cases to obtain graft material. It is important to realize that a rhinoplasty is really an “*aesthetic septorhinoplasty*” and one must deal with all the functional aspects of a cosmetic case. I am convinced that 35% of the pure cosmetic rhinoplasty patients have a fixed anatomical nasal obstruction that will cause postoperative obstruction unless it is fixed during the operation. Thus, a septal harvest is also a septoplasty of the septal body that will improve nasal function in many cases. If one is going to do rhinoplasty surgery, one must become comfortable with all aspects of septal surgery including caudal septal relocation.

Q. How often do you do spreader grafts?

A. The percentage is around 75% with half for function and half for aesthetics. The larger the reduction is, the more frequent the use of spreader grafts to avoid an inverted-V deformity. Certainly, any reduction over 2 mm converts the Y-shape dorsum at the rhinion into an I-shape central septum with potential collapse of the upper lateral cartilages and blockage of the internal valve. Fully, half of my spreader grafts are made asymmetric in width to correct preoperative asymmetries. I have never regretted inserting spreader grafts, but I have regretted not doing them. It is my opinion that “spreader flaps” can be used for minimal problems, but are not a full-service solution.

Q. Why the columellar strut?

A. The columellar strut is almost magical in its beneficial effects on the tip. The columellar strut and its suture serve three purposes: tip stability, tip projection, and columellar shape. The strut fosters verticality and projection of the tip while eliminating plunging of the tip on smiling. Suturing the alars to the strut creates a unified tip complex and improves symmetry. It is this tip that can be positioned with the tip position suture to create a supratip set off. Equally important, the strut provides a rigid intrinsic shape for the columellar thus reducing the influence of a deviated caudal septum.

Q. How flexible is the tip suture operation?

A. The tip suture technique that I advocate is essentially a “sew until its perfect” procedure. One normally sets the foundation of the tip with the strut (strut suture), then creates tip definition (domal creation suture), narrows tip width (interdomal suture), reduces asymmetry (domal equalization suture), and then achieves the desired supratip break as well as projection and rotation (tip position suture). One stops when the tip looks great with the skin closed. Only those steps are done which the anatomy mandates. For example, one may not need a domal creation suture on both sides, or the symmetry is excellent and a domal equalization suture is not done. There are no special sutures or instruments required. All of this is done with off the shelf sutures of 5-0 and 4-0 PDS.

Q. Why should I follow the Level approach and learn the basic operation?

A. If you have just entered practice, both your clinical experience and surgical skill set are finite, while the variety of noses is infinite. If every good result brings you three referrals and every bad result loses you nine, why start with the hardest cases? Obviously, one of the goals of this text is to teach you to recognize the various levels of difficulty and help you select appropriate patients. Surgically, most residents finish their training having done less than 20 cosmetic rhinoplasties with minimal follow-up. Their understanding of surgical cause and effect is marginal at best. For the first few years in practice, one should concentrate on learning a single expandable operation. Meticulous records must be kept as they allow the surgeon to evaluate their results at each postoperative visit. Although every step of the basic operation does not need to be done in every patient, I am convinced that each step will be needed in your first 25 rhinoplasties. Thus, it makes sense to learn the basic operation as a collection of surgical techniques which the surgeon selects from to design the optimal operative plan for the individual patient.

Decision Making Level 1: Planning a Rhinoplasty

Step #1: The Consultation. A rhinoplasty will be successful only if it achieves what the patient wants. Therefore, you must have the patient's point in the mirror at what three things bother him or her the most. Write them down on the operative planning sheet. Most women want a smaller more feminine nose with a lower profile, narrower width, and a more refined tip. Next, it is your turn to examine the nose externally and internally. Decide what the negatives are and what can be achieved realistically given the patient's anatomy. Sketch out a proposed operative plan – how much reduction, what type of osteotomies, tip surgery, any base modification, and functional factors. Assess the level of difficulty and whether this case fits within your comfort zone. After talking with the patient, determine whether you want this patient in your practice. Standard nasal photos of the patient are taken assuming you both wish to proceed. The patient is asked to bring photos of noses they like to the next appointment. As shown in the DVD of Fig. 2.22, the importance of the intranasal exam cannot be over emphasized.

Step #2: The Pre-op Visit. Early in one's practice you should do a photo analysis on all patients as it trains you to "see" the deformity and the solution. The critical sequence is to define the deformity, to superimpose the ideal, and then determine what is surgically feasible. When the patient returns, examine the nose again without looking at your notes – you want to see what is wrong with the nose and visualize what a rhinoplasty can achieve. Then open your notes, give the patient a mirror and ask her to tell you what bothers her the most in the order of importance. Check her requests against your operative plan. Then look at the pictures of the noses that the patient likes. Then review the operative plan and make any necessary changes. Write out a step-by-step individualized operative plan.

Step #3: The Operation. The advantage of spending the time to write out a detail step-by-step operative plan is that the vast majority of operations go according to plan. You can concentrate on surgical execution and efficiency rather than surgical decision making. Yes, slight changes may be necessary based on actual anatomy (add-on graft, alar rim graft, etc.), but you are not staring at the nose wondering what to do next. It is wise to take a four-view set of photos of the exposed finished tip before closing. At the end of the operation, a detailed op diagram is made which records every step and any questions you might have as to surgical cause and effect (Fig. 2.22d).

Step #4: Postoperative Follow-Up. The patient is seen a week later and the cast removed. The chart is opened to the op diagram page which allows you to assess surgical cause and effect. With the patient holding a mirror, the patient is taught how to tape their nose for compression. They are urged to wear the tapes for another 2–3 days and then tape at night for 3 weeks. They are given a set of their preoperative photographs. Return visits are scheduled at 1, 3, and 6 weeks with additional visits at 4 and 12 months.

A Basic Rhinoplasty Operation: Operative Sequence

- 1) Essentials – 2.5x loupes, fiberoptic headlight, own instruments.
 - 2) General anesthesia with appropriate monitors.
 - 3) Local anesthesia injection, then preparation – wait for 10–15 min.
 - 4) Remove intranasal nasal pack and shave vibrissae.
 - 5) Open approach using infralobular and transcolumellar incisions.
 - 6) Elevation of skin envelope.
 - 7) Septal exposure via transfixion incision and extramucosal tunnels.
 - 8) Reassess operative plan based on alar and septal anatomy.
 - 9) Creation of symmetrical alar rim strips.
 - 10) Incremental hump reduction – rasp:bony, scissors:cartilage.
 - 11) Caudal septum/ANS excision.
 - 12) Septal harvest/septoplasty.
 - 13) Osteotomies.
 - 14) Graft preparation.
 - 15) Spreader grafts.
 - 16) Columellar strut and suture.
 - 17) Tip sutures.
 - 18) Closure.
 - 19) Alar base modification.
 - 20) Alar rim support grafts (ARS).
 - 21) Doyle splints and external cast and nasal block.
- Note: all steps are considered, but only those steps indicated are actually used.

What Are the Most Common Variations?

- 1) Cartilaginous dorsal *reduction* is achieved primarily by excising the isolated dorsal septum, while *dorsal narrowing* is achieved by excision of upper lateral cartilage. The ratio is often 3:1 with minimal ULC resection.
- 2) The caudal septum is altered in less than 50% of the cases and the ANS in less than 5%.
- 3) The majority of septal problems in cosmetic cases are deviations of the septal body or caudal septum. A septal harvest often corrects the former while a relocation fixes the caudal septum.
- 4) Osteotomies are not done in 10% of the cases as the bony vault is quite narrow preoperatively and one does not want to reduce the nasal airway.
- 5) Spreader grafts are not done in 25% of the cases because the dorsum was reduced less than 2 mm. The majority of paired grafts are asymmetric and 50% are inserted for aesthetic reasons.
- 6) Tip sutures are sufficient in 75% of the patients with 20% having add-on grafts of excised alar cartilage. A true tip graft of septal cartilage is used in less than 5% of Caucasian patients, but 95% of Asian patients.
- 7) Initially, alar base modification should be something that the patient requests (smaller nostrils) rather than something that the surgeon suggests. Conservatism is essential.
- 8) Alar rim grafts may be necessary to minimize alar rim weakness. They are easily placed in subcutaneous pockets that parallel the alar rim.

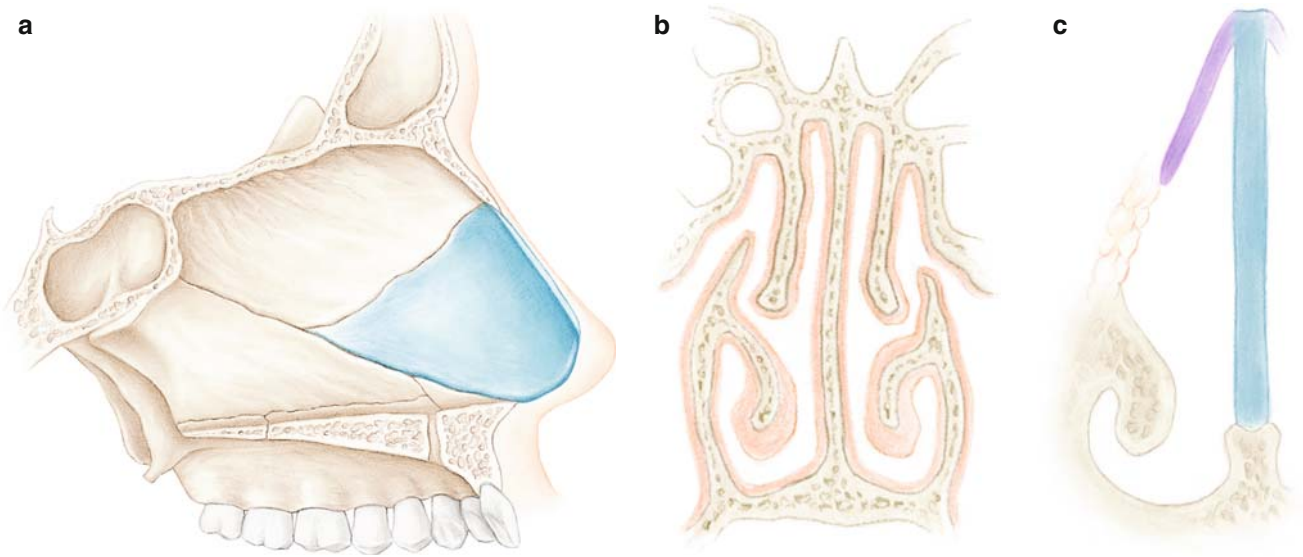


Fig. 2.19 (a–c)

Table 2.3 Photographic analysis

Anterior	Lateral	$N-T_i = 0.67 \times MFH$ $AC-T_i = 0.67 \times N-T_i$ $C-N_i = 0.28 \times N-T_i$		$N-T_i =$ $AC-T_i =$ $C-N_i =$	
			Actual	Ideal	Change
EN-EN =	C-N =	N			
X-X =	AC-T =	T			
AL-AL =	N-C' =	SN			
AC-AC =	N-SN =	NFA			
IDD =	N-FA =	TA			
MFH =	TA =	CIA			
LFH =	CIA =	C-N			
SME =	CLA =	N-T			
		AC-T			

Septorhinoplasty - Operative Procedure

Rollin K. Daniel, MD

LAST NAME

CASE NUMBER

DATE

INCISIONS AND APPROACH

- Incisions: INTER INTRA INFRA Trans-columellar
 Transfixion-Unilateral Transfixion-Bilateral Killian
 Approach: Closed Open Closed/Open
 Retrograde Trans-cartilagenous Delivery

NASAL TIP

- UNTOUCHED
- Cephalic Resection: Retrograde Trans-cartilage Delivery Open
 Delivery: Cephalic resection Incisions Lateral seg. excision Domal excision
 Sutures: Intradomal Transdomal Creation
 Other: _____
- Tip Graft: Peck Juri Other: _____
- Sheen Graft: Type I - crushed Type II - bruised Type III - solid Type IV - backstop
- Open Structure: Suture Graft Domal excision Other: _____
- Comment:

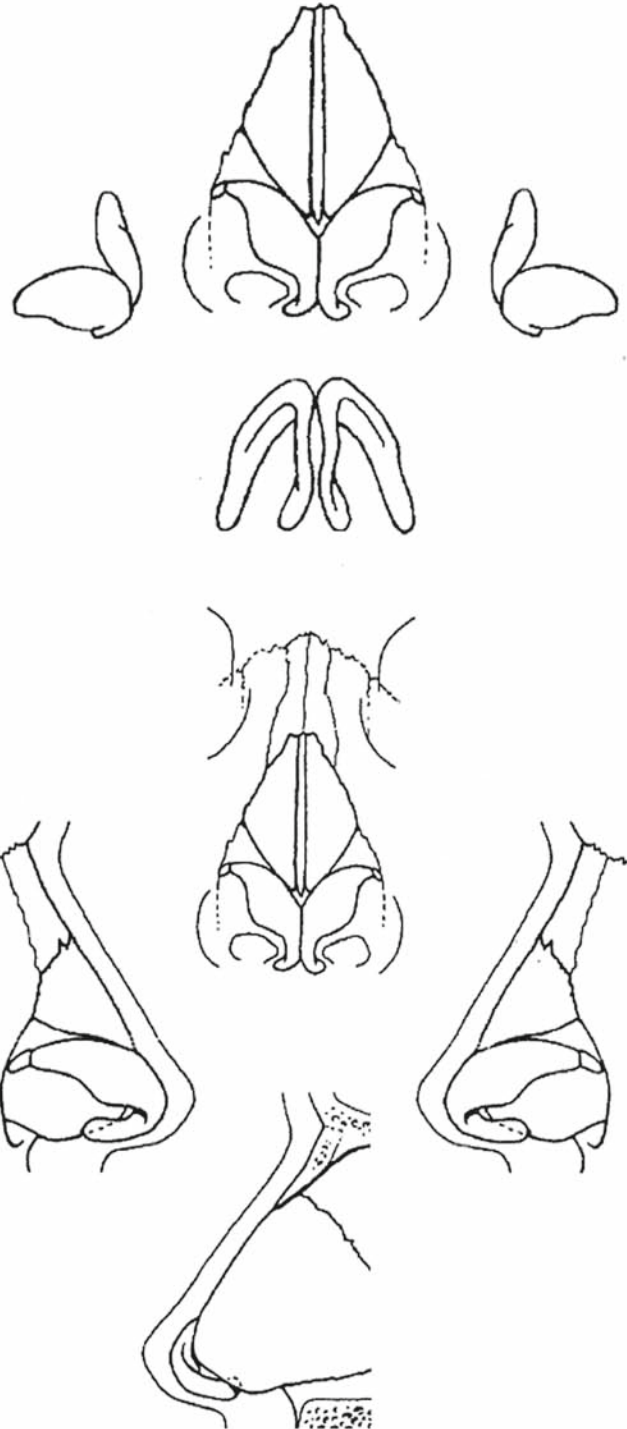
DORSUM

- UNTOUCHED
- Dorsum: Untouched Lowered Augmented Smoothed
 Other: _____
- Radix: Reduction - rasp Reduction - osteotome Augmented - single graft Augmented - multiple graft
 Other: _____
- Bone: Rasp Osteotome Other: _____
- Cartilage: Lowered Augmented Shortened Spreader
 Other: _____

OSTEOTOMIES

UNTOUCHED

	Right	Left
LATERAL	None	
	Low-high	
	Low-low	
	Double level	
TRANSVERSE	None	
	Digital	
	Osteotome	
MEDIAL	None	
	Medial	
	Medial Oblique	
CONTINUOUS		
MOVEMENT	Greenstick	
	Complete	



© Copyright 1992 Rollin K. Daniel, MD and Ronald G. Zelt, MD

Fig. 2.20

Case Study:
Aesthetic
Septorhino-
plasty (Level 1)

Analysis. A 16-year-old girl presented for a rhinoplasty (Fig. 2.21). She stated that she did not like her profile and that her breathing was normal. The external exam revealed a deviation of the caudal septum to the left. On profile and oblique view, she had a “tension nose” and a high potential for an inverted-V deformity. On internal exam, the septum totally blocked the right airway while the caudal deflection blocked the left external valve. Aesthetically, this is an easy case to obtain an excellent result. An incremental dorsal reduction (2 mm bone, 4 mm cartilage) and 4 mm of caudal septal resection was done. In addition, a chin implant gave better balance to the face. Yet the case illustrates the necessity of being able to correct septal deviations and doing spreader grafts for functional and aesthetic purposes. Thus, both techniques are part of the basic rhinoplasty operation.

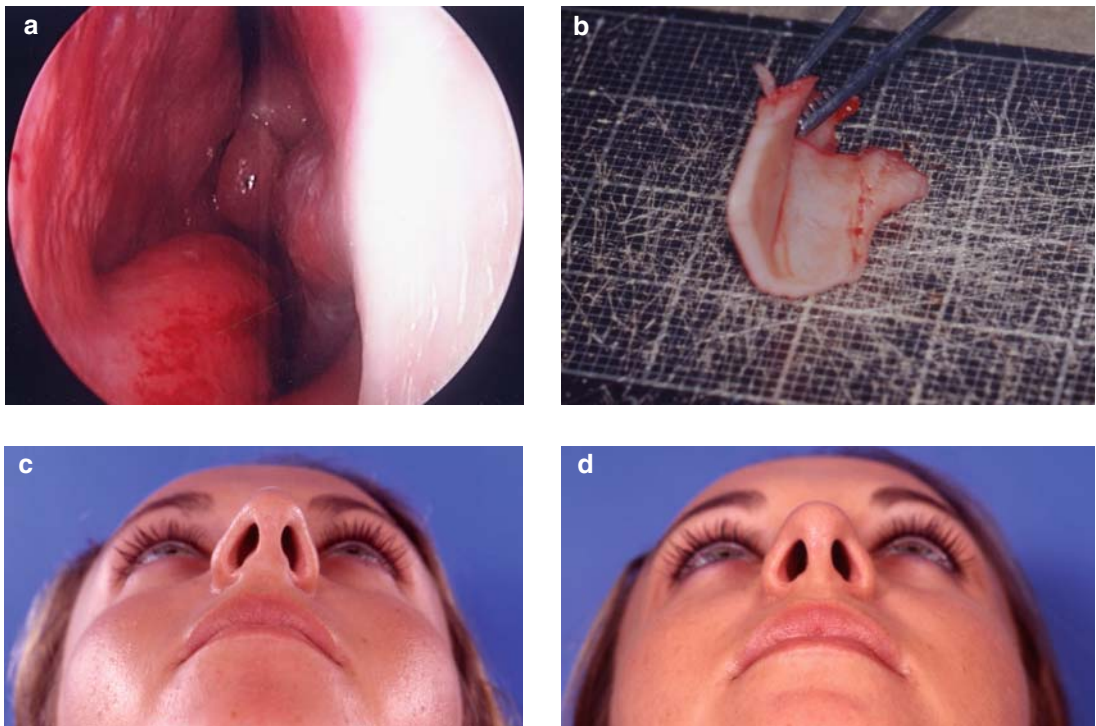


Fig. 2.21 (a-l) (a) Endoscopic view of septal deviation, (b) Septal harvest corrected deviation of septal body, (c,d) caudal septal relocation

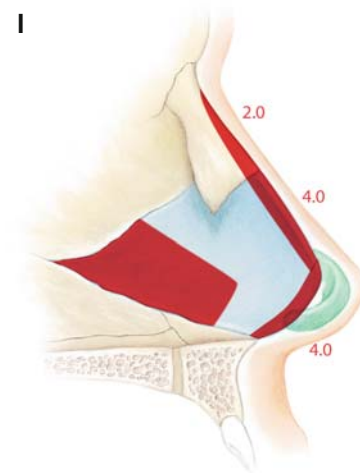
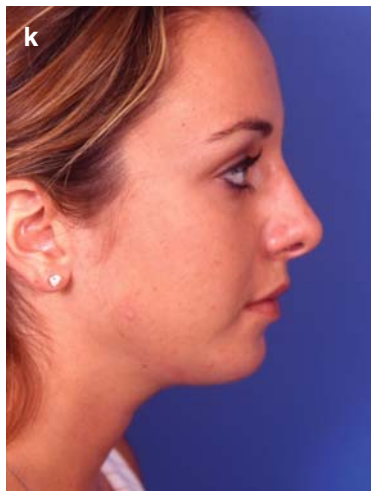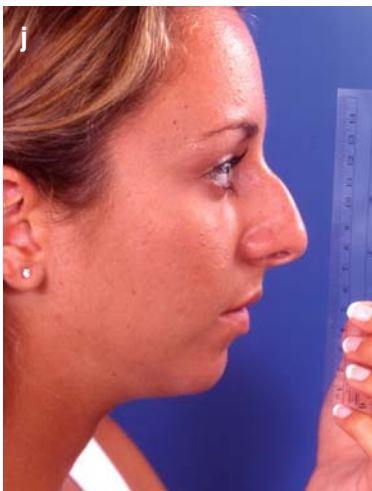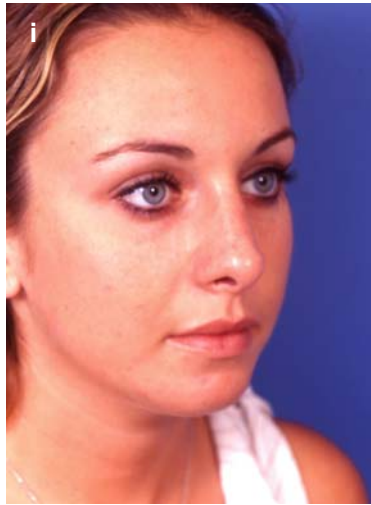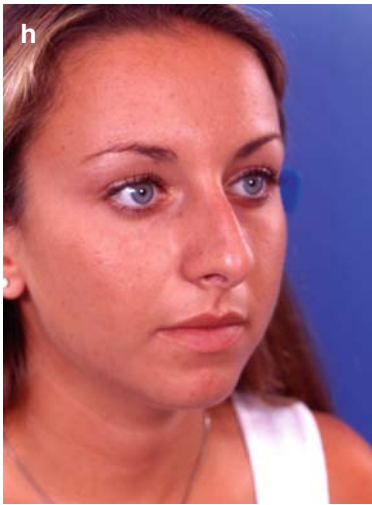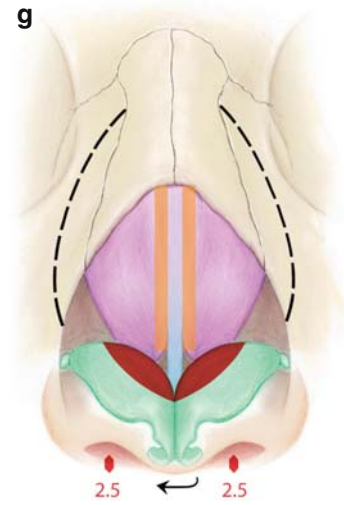


Fig. 2.21 (continued)

Decision Making Level 2: The Harder Nose

Each surgeon must develop their own criteria for assigning a degree of difficulty to each nose, from Level 1–3. Perhaps, the best method is to use a classic “standard deviation” system based on deviation from normal (Fig. 2.22). Each of the six tip criteria can be analyzed as well as skin thickness. After assessing the tip, a degree of difficulty is assigned for the dorsum, base, and septum. Added to the mix are patient factors and history of trauma or nasal obstruction. Here are a few of my own criteria and concerns.

Patient Factors. Is this patient psychologically a candidate for surgery and would a rhinoplasty make a real difference in their appearance? How would this patient cope with a complication? What is my margin of error? How close can I come to achieving what the patient wants? Am I comfortable with this patient and the operative plan?

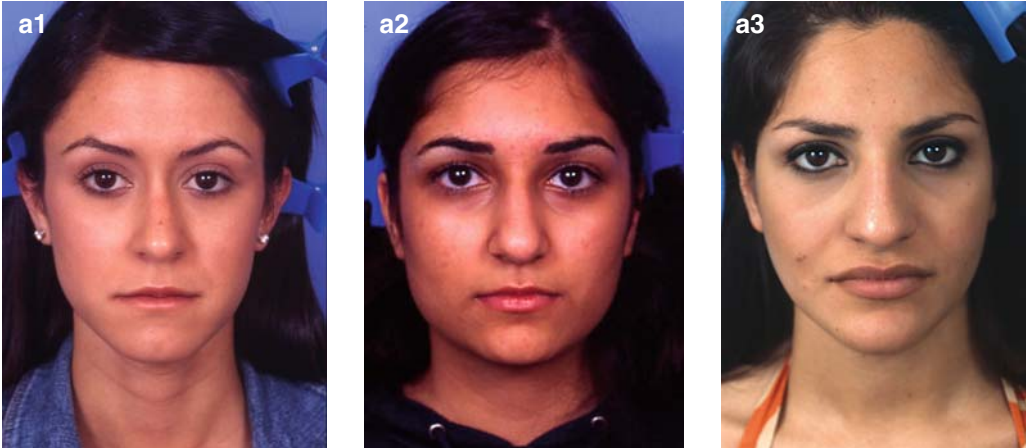
Surgical Factors.

1. **Tip.** In most Level 2 cases, the challenge is bringing the tip back into the normal range without having to fundamentally change its shape. An example is the difference between a broad tip (Level 2) which requires aggressive suturing and perhaps add-on grafts versus an over projecting ball tip (Level 3) which may require alar transposition plus lateral crura strut grafts.
2. **Dorsum.** Level 2 cases often differ from Level 1 cases quantitatively – the amount of reduction and its cephalic extent are often greater. Spreader grafts are now a necessity. Any radix graft will be fascia and occasionally have diced cartilage beneath it. All full-length augmentations or major radix reductions are Level 3.
3. **Base.** Assigning a level for the base is most easily determined from the surgical plan. For example: Level 1 (nostril sill or alar wedge), Level 2 (combined nostril sill/alar wedge with alar rim graft), or Level 3 (major combined excisions in the ethnic nose). In Level 2 cases, one must be comfortable with all types of base excision and the standard alar rim grafts (ARG, ARS).
4. **Septum.** The more difficult septums are those with severe deviations due to developmental or traumatic etiologies. Correction may require dorsal splinting and division which can be challenging. Once comfortable with restoring dorsal stability and replacing the caudal septum, one can do a total septoplasty – a very frightening maneuver when done for the first time. Severe posttraumatic and secondary septums are considered Level 3 as there is no certainty as to how complex the surgery will become including possible rib grafts.

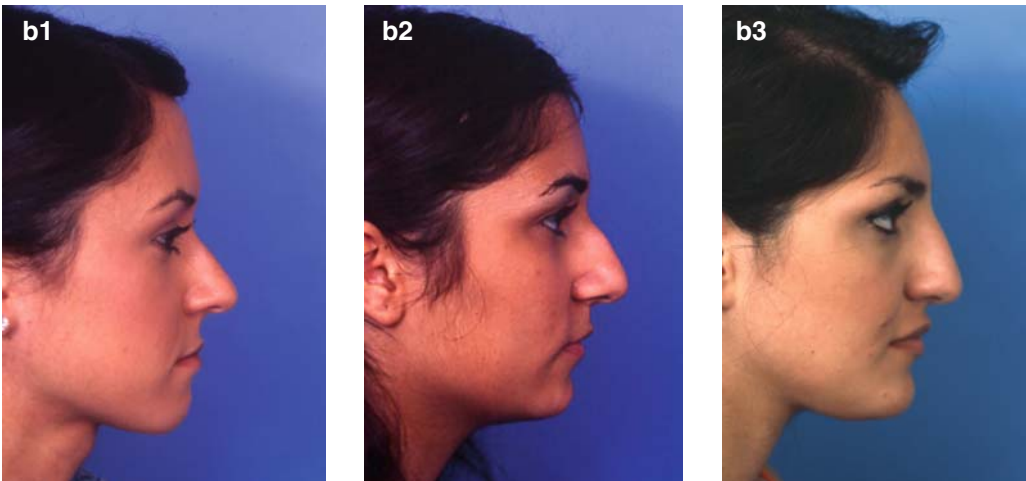PRINCIPLES

- The simpler the operative plan is, the greater the chance of success.
- Transition from Level 1 to Level 2 cases by picking cases where only one or two areas of the nose are harder – not all aspects.
- Make sure the nose looks significantly better at the end of the operation – continue until it is as good as you can do.
- Never hesitate to take out sutures or grafts that are not perfect.

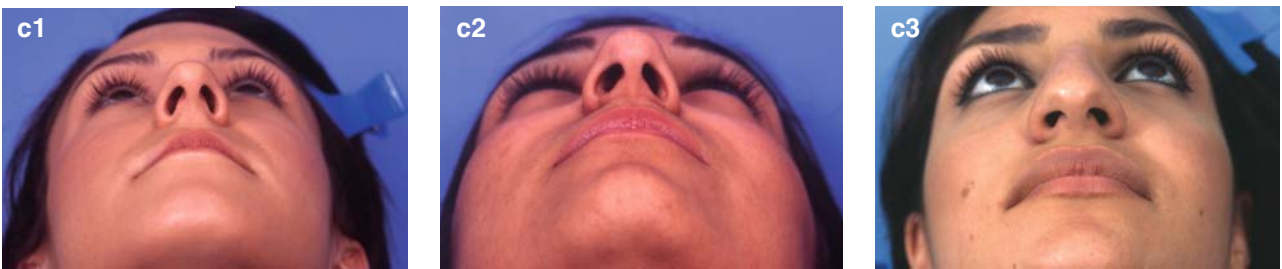Tip width (Level 1-3)



Dorsum (Level 1-3)



Nasal base (Level 1-3)



Septum (Level 2+)

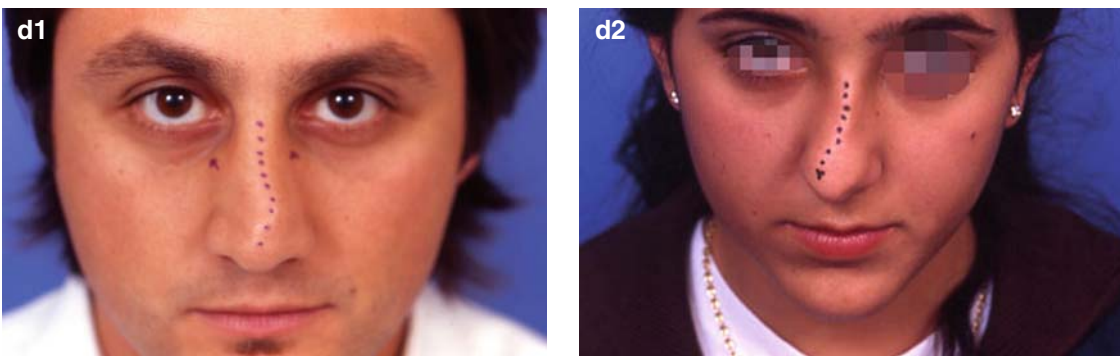

Fig. 2.22 (a-d) (Level 1-3) cases

Case Study: The Plunging Tip (Level 2)

A 17-year-old Hispanic girl complained of her profile view and that the nose plunged when she smiled (Fig. 2.23). On lateral view, the dorsum was normal height while the radix was low. On anterior view, the dorsum was wide both dorsally and laterally. A “balanced approach” was used with radix augmentation and tip support. The caudal septum was shortened 6 mm which eliminated downward pull on the tip when smiling. The ability to rotate the tip upward was achieved with the columellar strut and a dorsal positioning suture. Narrowing of the dorsal and lateral width without lowering the dorsum was achieved using parallel dorsal and lateral osteotomies. At 4 years post-op, the patient has done well.

Operative Technique Highlights

- 1) Exposure of the nose – no dorsal reduction
- 2) Caudal septal resection of 6 mm and septal harvest
- 3) Paramedian and low-to-low osteotomies
- 4) Crural strut and tip sutures: CS×2, DC, ID, DE, C-S
- 5) Radix graft of diced cartilage in fascia (0.5 cc)
- 6) Nostril sill excisions 2.5 mm
- 7) Small chin implant

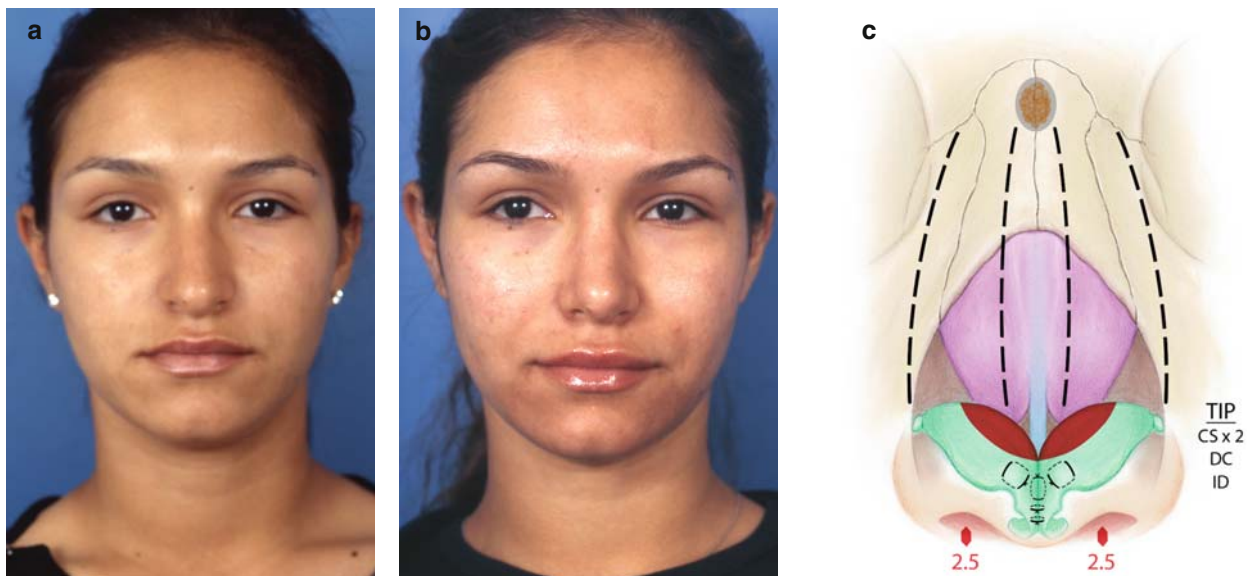


Fig. 2.23 (a-j)

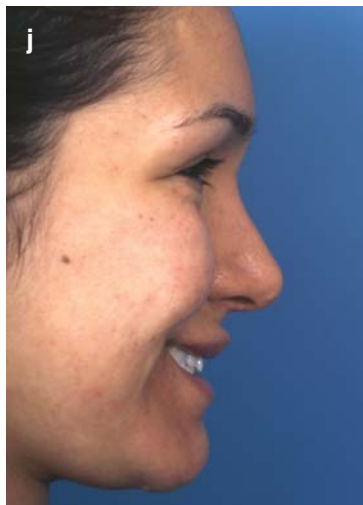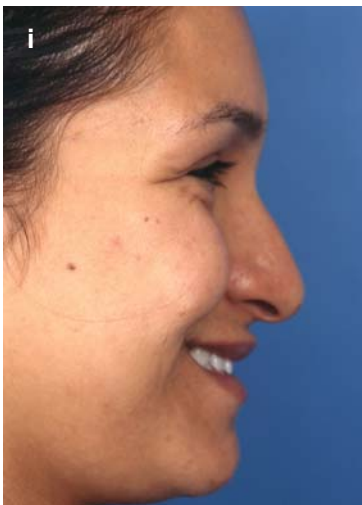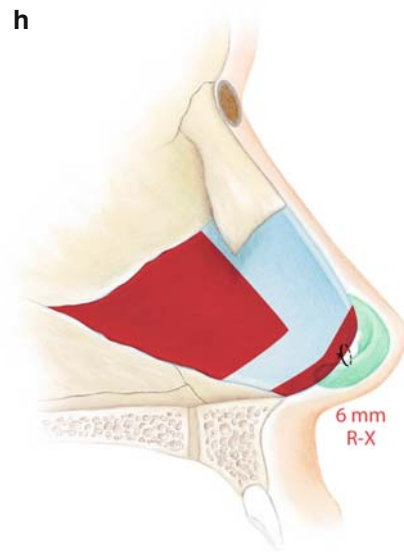


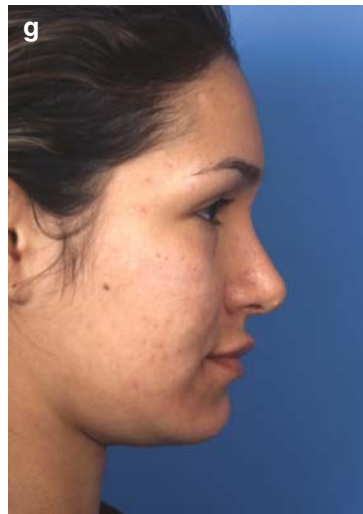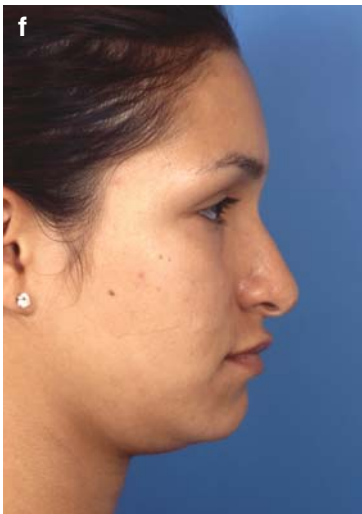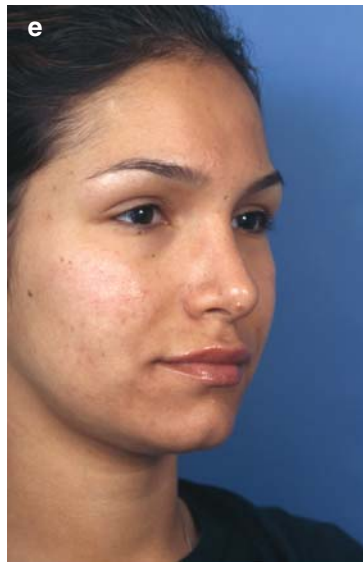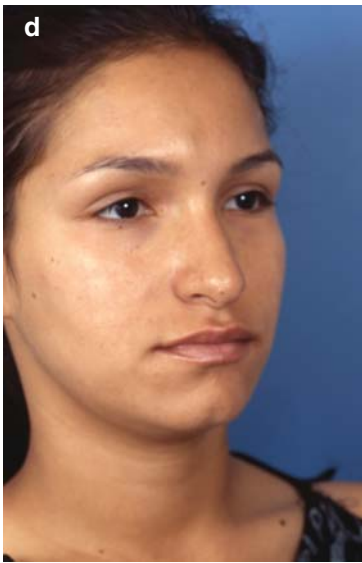Fig. 2.23 (continued)

Decision Making Level 3: The Difficult Nose

Level of Difficulty. Put simply, a Level 3 nose is one whose anatomical deformity limits the achievement of an excellent result. Often, the skin will be too thick, the alars too asymmetric, or the entire nose is unattractive. Early in my practice, I could always recognize these cases because I did not sleep well the night before surgery. The result was that I spent hours in the operating room sweating the details and then months in the exam room listening to the patients complain. A smarter surgeon would have recognized them at consultation and passed on doing them until their surgical skill set had expanded. What should you do?

First, you have to develop your own individual set of “*aesthetic*” criteria for grading Level 1–3 cases based on the presenting deformity. You must reconcile both the patient’s deformity and requests with your surgical ability to achieve the patient’s goal. In the first few years of practice, there is nothing wrong with a “one third distribution” for each level of difficulty. Second, as you gain experience and progress from Level 1 to Level 2 cases you can shrink the percentage of cases assigned to Level 3. Third, experience will give you the judgment and confidence to do more difficult cases.

Expansion of Operative Techniques. Level 3 cases demand both *excellence* of the fundamental steps in a rhinoplasty operation and *expansion* of the skill set. For example, virtually all types of grafts may be required from columellar struts to tip grafts to alar grafts. A radix reduction is a magnitude harder than a radix augmentation. A combined nostril sill/alar base resection is a grade more difficult than an alar base resection. Ethnic noses are more challenging than the usual Caucasian nose. As regards the tip, an open structure tip graft signals a harder case than a suture tip. Yet, an open tip graft added to sutured domes is easier than one where the domes are excised to drop projection. One may encounter severe alar malposition under thin skin which requires alar transposition and coverage with a fascial blanket graft.

Transitioning from Level 2 to Level 3. For most surgeons, the transition from Level 2 to 3 cases will be gradual and sometimes unplanned. For example, when dealing with a combined large nose and tip, it becomes necessary to reduce both. The dorsum is reduced first in increments and suddenly the tip looks relatively enormous. The planned open tip suture procedure will not reduce the tip. Rather, domal excision and tip grafting becomes obligatory. Yes, it would have been ideal to have decided on this op plan first, but the unexpected happens. Obviously, preoperative planning is better and identification of a subset of patients that require more sophisticated techniques is the goal. In my own practice, the transition from Level 2 to 3 was possible by operating on easier Asian and Type II Hispanic noses. Preoperatively, one knows that the skin envelope will be thick, the need for structure great, dorsal augmentation frequent, and alar base reduction demanding. These cases require sophistication and are probably Level 2.5 which makes them ideal for transitioning to Level 3 (Fig. 2.24).

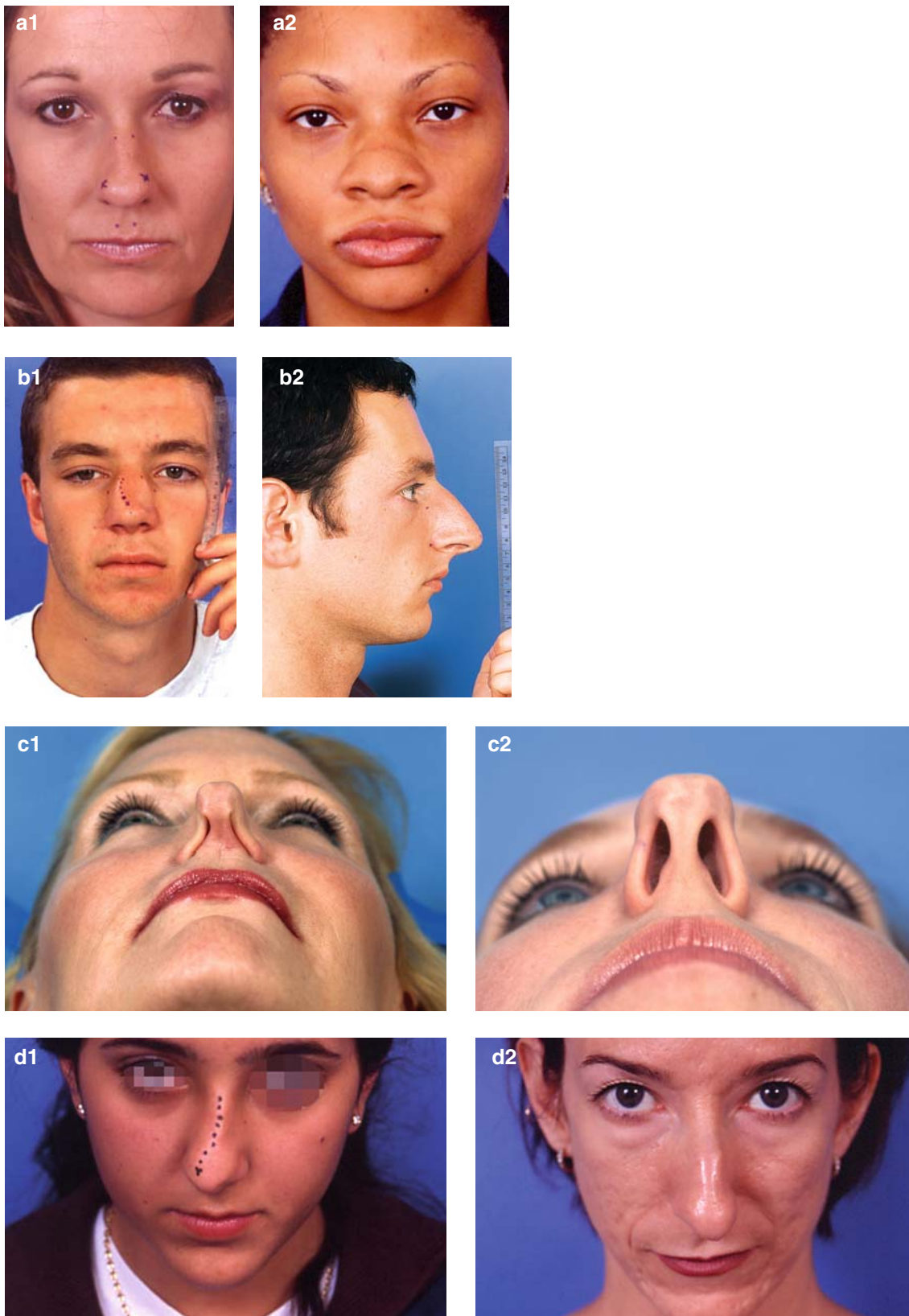


Fig. 2.24 (a–d) Level 3 cases

Case Study: The Ball Tip (Level 3)

A 44-year-old woman wanted a rhinoplasty because she hated her large round tip (Fig. 2.25). The size of the tip was compounded by the juxtaposition of a narrow dorsum. There was no alar malposition. She had a deep alar cartilage – A1 junction compressing the vestibular valve that collapsed on deep inspiration. After extensive discussion, she made it clear that she wanted a “smaller model’s tip.”

There was nothing simple about this nose from either an aesthetic or a functional perspective. One had to excise the strong ball-shaped alar cartilages in the presence of vestibular and nostril valve collapse. Six functional steps were done to provide structure: (1) a columellar strut, (2) lateral crural strut grafts, (3) the septoplasty aspect of the septal harvest, (4) major spreader grafts, (5) out fracture of the turbinates, and (6) the decision not to do lateral osteotomies. By comparison, direct excision of a domal segment and coverage with a tip graft of excised cartilage was straightforward.

Operative Technique

- 1) Exposure disclosed round alar cartilages 14 mm in width.
- 2) Incremental dorsal reduction (bone 1 mm, cartilage 4 mm).
- 3) Septal and fascial harvest.
- 4) No osteotomies.
- 5) Bilateral spreader grafts.
- 6) Create 6 mm rim strips.
- 7) Insertion of crural strut. Excision 5 mm domal segment.
- 8) Repair of domal excision. Coverage with an alar concealer graft.
- 9) Excision of alar – A1 junction. Insertion of lateral crural strut grafts Type I.

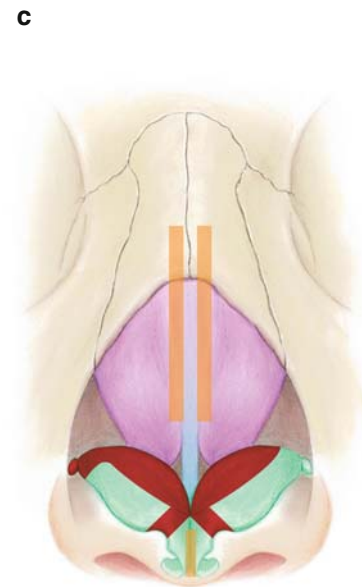
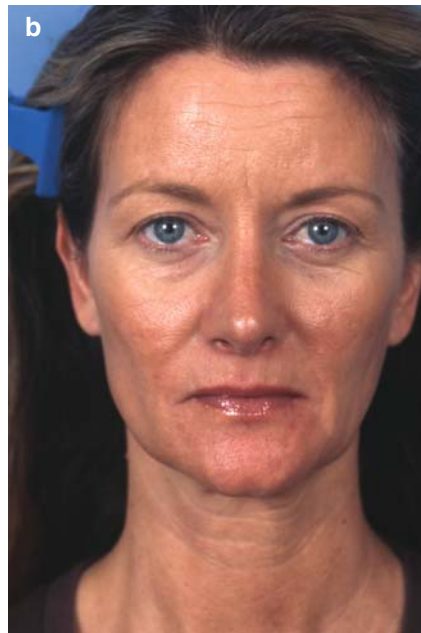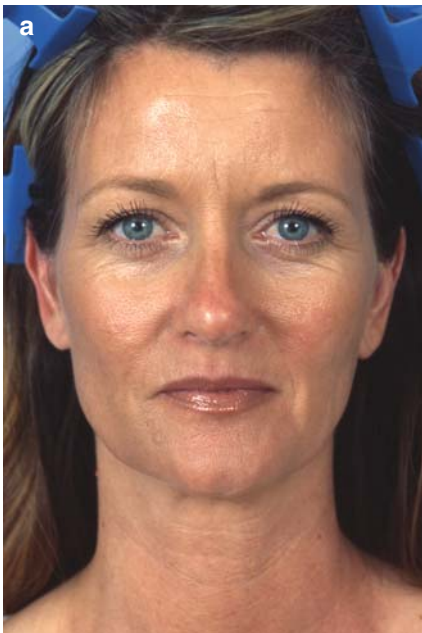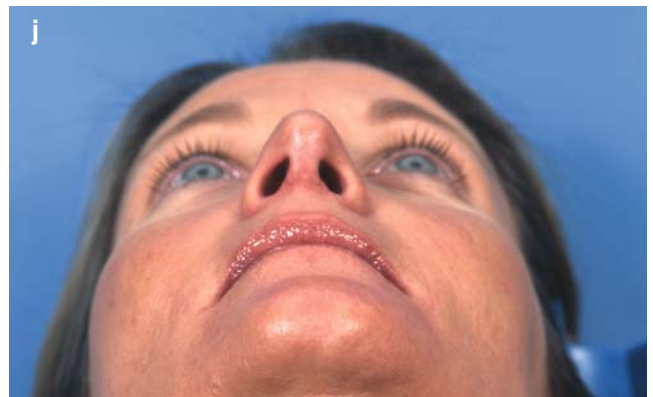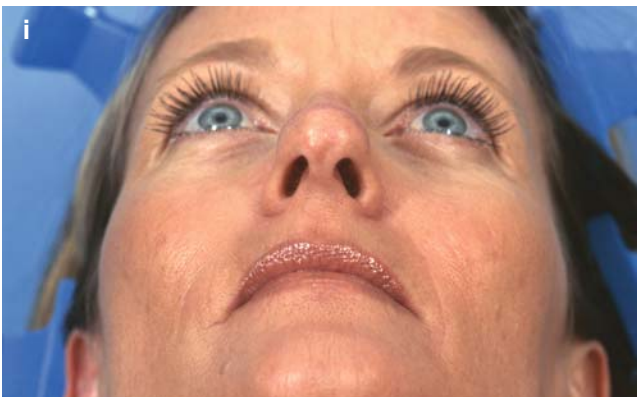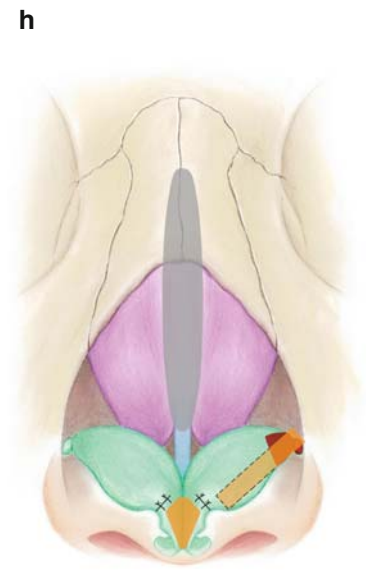


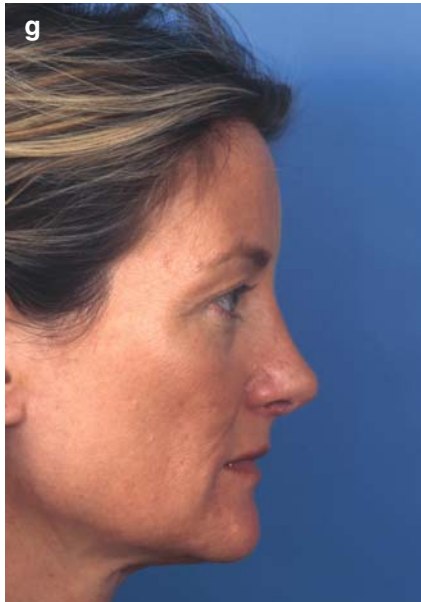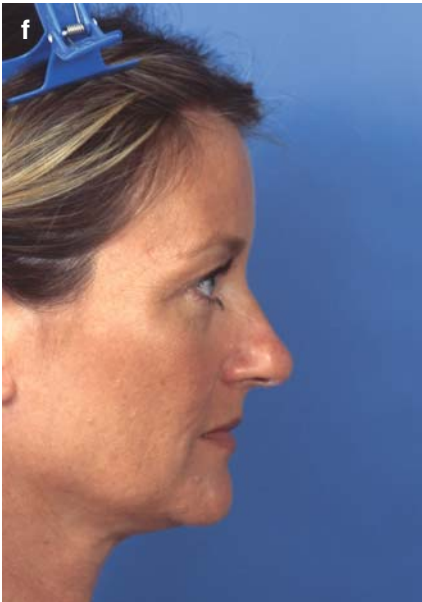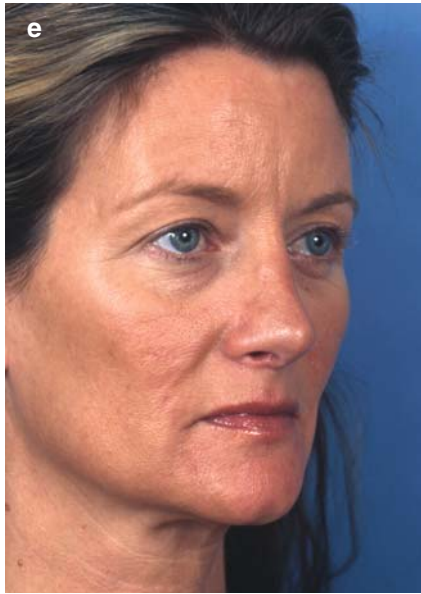Fig. 2.25 (a-j)



Postoperative Management

The smoothness of the postoperative course is directly proportional to the thoroughness of the preoperative preparation. Another copy of the “10 Most Frequently Asked Post-Op Questions” is given to the patient’s caregiver. The patient is instructed to begin pain medication and oral antibiotics (Ciprof 500 mg BID for 5 days). Head elevation and ice compresses over the eyes for 36 h are recommended. The drip pad is changed as necessary. Meticulous cleaning of all suture lines two to three times a day with hydrogen peroxide and coverage with antibiotic ointment is stressed. The patient is seen 1 week later. On the morning that the cast is to be removed, the patient is instructed to take a shower and get the cast and nose wet. They are also told to take a pain pill 30 min before coming to the office. The sequence of removing the dressing is as follows: (1) the acrylic cast is lifted off by gentle rocking (the Telfa dorsal strip allows it to come off without pulling the skin), (2) the Steri-strips are removed, (3) the intranasal splints are extracted after the suture is cut on the left side, (4) all external sutures are removed, and (5) the nose is gently cleansed with hydrogen peroxide. The patient is allowed to see the nose with a mirror; especially the profile view with the preoperative lateral photograph held beside the head for comparison. Then the patient is taught how to tape and also given a step-by-step “taping diagram” plus a roll of tape. The technique is as follows: (1) four 2 cm pieces, one 4 cm piece, and one 6 cm piece of 0.5 in. flesh-colored paper tape are cut, (2) three short pieces are slightly overlapped on the dorsum, (3) the medium and long piece are placed longitudinally along the edge of the dorsum, (4) the distal ends are pinched together to narrow the tip and the longer piece rotated to the opposite side, and (5) the final short piece is placed transversely to set off the tip. The patient is encouraged to tape the nose at night for 3 weeks to reduce swelling. In patients with thick skin, taping may be done for 4–6 weeks. If the nostrils have been narrowed extensively or I am concerned about their shape then “nostril splints” are inserted prior to the taping. Patients will use the nostril splints at night, unilateral or bilateral, for 1–3 weeks. When turbinates and complex septal surgery are done, the patient is encouraged to irrigate the nose with a generic salt water spray. The patient is seen 2 weeks later and then at regular intervals: 3, 6, and 12 months and then annually, thereafter. The usual concerns include bruising, swelling, breathing, smiling, numbness, and initial appearance.

Ecchymosis and Edema

Bruising and swelling are a normal occurrence following a rhinoplasty. Since the patient must be off aspirin for 2 weeks prior to surgery, bruising rarely persists for more than 1 week. Some patients do have a residual bruising in the malar area that can be covered up with makeup and an unfortunate few do get scleral hemorrhage that may persist for 3–6 weeks. Very rarely, a patient of Mediterranean descent will get dark circles beneath their eyes which require a course of 4% solaquin forte. Patients are told preoperatively to expect swelling and that it will regress in two stages. Stage I is a generalized swelling that reduces uniformly over the first 2–3 weeks. Stage II is a more gradual period of scar remodelling that follows a constant pattern: bony dorsum 3 months, cartilaginous dorsum 6 months, supratip area 9 months, and tip 12 months. I emphasize to the patient that they lose one third of their tip

swelling by 2 months, the next third between 3 and 9 months, and the final third between 9 and 12 months.

Breathing

Most patients breathe well, especially after removal of the intranasal splints. They are warned that the splints have been compressing the mucosa and that a rebound swelling may occur for a week or so. They are encouraged to use a nasal spray to replace normal nasal secretions and mechanical cleansing, both of which are often reduced temporarily following surgery. During the winter, a humidifier and coating the vestibule/caudal septum with vaseline is often encouraged to counteract the drying of forced air heating.

Initial Appearance

Before the cast is removed, the patient is reminded of the preoperative admonitions: (1) the nose will be swollen, (2) the nose will look swollen on front view, but the lines of the nose will be visible on profile view, and (3) the tip may appear a bit turned up at first. The patient is reassured that their nose will look better the minute the cast is removed than it did preoperatively and that it will gradually get better and better. Also, they are told that the nose will swell on recumbency and not to be surprised if the nose swells more on one side than the other depending on which side they sleep on. Night time taping is encouraged.

Smiling

When extensive septal work is done including relocation of the caudal septum, it is not uncommon for the patient to complain of a weak smile and limited exposure of their upper teeth. Release of the depressor septi nasalis is the cause and complete return usually occurs by 4–6 weeks. It is best to warn the patient of this potential occurrence preoperatively.

Numbness

Many patients complain that their nose is numb postoperatively. Its occurrence is due to the severance of the continuation of the anterior ethmoidal nerves. Although most surgeons consider it a minor problem and one that always resolves within 6 months, my experience has been different. It is my impression that the return is often much longer (12–18 months) and often partial rather than complete. Again, a prepared patient will more easily accept some reduction in sensation.

Complications

In contrast to the expected associated morbidity of any operation, complications are neither desired nor easily accepted by the patient. The surgeon must inform the patient about the usual risks and give some idea of their incidence and management. For some surgeons, their biggest error is not the occurrence of the complication, but rather their attempt to ignore it or mismanage it. The admonition to be forthright, honest, compulsive, and caring will resolve even the most trying of situations.

Incidence

It is virtually impossible to get an accurate indication of postoperative complications. In absolute terms, my complications for the 100 cosmetic cases with a mean 18-month follow-up would be as follows: hemorrhage 1%, infection 0%, septal perforation 1%, skin slough 0%, scar visibility 0%, nasal obstruction 1%, and revisions 5%. Although the data is accurate, the conclusions are merely a “snapshot” of my practice over a specific time period. For example, I went 7 years without a postoperative bleed and then had three in 3 months. To my knowledge, this is the first septal perforation I have had in over 1,000 rhinoplasties in the last 6 years. Thus, is the true incidence of septal perforation 1% or 0.1%? The surgical saying is “if one does enough surgery, one will eventually have every complication” be prepared.

Hemorrhage

Following recognition of the role that aspirin played in postoperative bleeding, the incidence of hemorrhage decreased significantly. In most cases, intraoperative bleeding can be controlled by cauterization and judicious packing with epinephrine-soaked gauze. Gentle compression over 5–10 min will allow better visualization and cauterization. My impression is that most major bleeds follow medial osteotomies or turbiectomy. In cases involving extensive septal and turbinate surgery, I insert Doyle splints plus gelfoam gauze to completely pack the airway and leave them for 5–7 days. Certainly, the management of postoperative hemorrhage has been greatly simplified by the introduction of nasal tampons (RhinoRocket). In my last three bleeding episodes, I have found that insertion of a nasal tampon was an excellent first step, and there was no need to progress to cauterization or a posterior pack.

Infection

Acute infection following rhinoplasty has decreased to less than 1%. I continue to use prophylactic antibiotics for 5 days postoperatively due to the large number of grafts. I have had two acute infections, both in small revision cases without any septal work or grafts. In both instances, they require aggressive treatment:

(1) incision and drainage, (2) gauze packing, (3) immediate broad spectrum antibiotic coverage plus high doses of penicillin, (4) cultures with subsequent adjustment of the antibiotic, and (5) daily office visits until resolution. Despite a horrendous appearance initially, both wounds healed without scarring, and no further surgery was required. Chronic infections with periodic swelling and erythema may be associated with an underlying mucosal cyst. *Toxic shock syndrome* (TSS) does occur following rhinoplasty and one must be aware of

its symptoms: (1) fever (101–103), (2) hypotension, (3) gastrointestinal tract symptoms (diarrhea, vomiting), (4) erythematous macular rash with eventual desquamation, and (5) exclusion of other infectious diseases. In all of the case studies, it is the combination of a lethargic, hypotensive, and very sick patient that is apparent. These patients must be treated as in a life-threatening emergency, admitted to the hospital, an infectious disease consultant brought in, all nasal packs removed, and the nasal airways cleansed.

Septal Problems

Unfortunately, septal hematomas, abscesses, and perforations still occur. I have seen one postoperative septal hematoma that required drainage. I made a unilateral inferior incision and then inserted bilateral silastic splints. The septal abscess followed a minor dorsal revision *without* any septal surgery. A fluctuant mucosa was obvious bilaterally. Purulent drainage occurred following incision and small length of 0.25 in. Penrose drain was sutured into the space to promote drainage. The drain was removed at 4 days, and there were no subsequent problems. Septal perforations following rhinoplasty are an infrequent occurrence. I am aware of producing at least three, but all have been small asymptomatic posterior holes which have not required treatment. Why did they occur? My explanation would be poor technique in one (perichondrium was removed with the septum on one side), mucosal factors in another (chronic friable mucosa in a woodworker), and nonspecific etiology in the latest one. In each case, the patient was told that the perforation was present and that surgical correction or a silastic button was the option if they became symptomatic.

Nasal Obstruction

The reported etiology and incidence of nasal obstruction following rhinoplasty is diverse. In the *early* period, the usual cause is intranasal swelling and lack of normal physiological functions. Certainly, mucociliary transport slows, resulting in stagnation and even obstruction. Cleansing the inside of the nose either by the physician or the patient using an over-the-counter saline spray will usually improve the condition. In the *late* period, one tends to consider either medical or anatomical etiologies. Obviously, a preoperative questionnaire should have revealed the extent of allergic or vasomotor rhinitis which on occasion will be exacerbated by greater airflow and associated environmental exposure. The appropriate combination of decongestants and nasal sprays can be instituted.

Reading List

- Aiach O. Atlas of Rhinoplasty (2nd ed). St. Louis: Quality Medical Publishing, 1996
- Daniel RK. Rhinoplasty: Creating an aesthetic tip. *Plast Reconstr Surg* 80: 775, 1987
- Daniel RK. (ed) Aesthetic Plastic Surgery: Rhinoplasty. Boston: Little, Brown, 1993
- Daniel RK. Open tip suture techniques. Part I: Primary rhinoplasty. Part II: Secondary rhinoplasty. *Plast Reconstr Surg* 103: 1491, 1999
- Daniel RK. Rhinoplasty: Nostril/tip disproportion. *Plast Reconstr Surg* 107: 1454, 2001
- Daniel RK. Rhinoplasty: An Atlas of Surgical Techniques. Berlin: Springer-Verlag, 2002
- Daniel RK. Rhinoplasty: Septal saddle nose deformity and composite reconstruction. *Plast Reconstr Surg* 119: 1029, 2007
- Daniel RK, Calvert JC. Diced cartilage in rhinoplasty surgery. *Plast Reconstr Surg* 113: 2156, 2004. Follow-up in: Daniel RK. Diced cartilage grafts in rhinoplasty surgery: Current techniques and applications. *Plast Reconstr Surg* 122: 1883, 2008
- Daniel RK. Tip Refinement Grafts the designer tip. *Aesth Surg J* (Nov), 2009.
- Goodman WS. External approach to rhinoplasty. *Can J Otolaryngol* 2: 207 (Entire Issue devoted to Open Rhinoplasty) 1973
- Gorney M. Patient selection in rhinoplasty: Practical guidelines. In: Daniel RK (ed) Aesthetic Plastic Surgery: Rhinoplasty. Boston: Little, Brown, 1993
- Gruber RP, Nahai F, Bogdan MA, et al Changing the convexity and concavity of nasal cartilages and cartilage grafts with horizontal mattress sutures. Part I. Experimental results. *Plast Reconstr Surg* 115:589, 2005. Part II Clinical Results. *Plast Reconstr Surg* 115: 595, 2005
- Gruber R, Chang TN, Kahn D, et al Broad nasal bone reduction: an algorithm for osteotomies. *Plast Reconstr Surg* 119:1044, 2007
- Gubisch W. Twenty-five years experience with extracorporeal septoplasty. *Facial Plast Surg* 22: 230, 2006 (Note: entire journal issue is devoted to septal surgery)
- Gunter JP. Secondary rhinoplasty: The open approach. In: Daniel RK (ed) Aesthetics Plastic Surgery: Rhinoplasty. Boston: Little, Brown, 1993
- Gunter JP, Rohrich RJ, and Friedman RM. Classification and correction of alar-columellar discrepancies in rhinoplasty. *Plast Reconstr Surg* 97: 643, 1996
- Gunter JP, Rohrich RJ, and Adams WP. (eds) Dallas Rhinoplasty: Nasal Surgery by the Masters. QMP,757, 2007
- Guyuron B. Dynamic interplays during rhinoplasty. *Clin Plast Surg* 23: 223, 1996. (Entire Issue)
- Guyuron B. Precision rhinoplasty. Part I: The role of life-size photographs and soft-tissue cephalometric analysis. *Plast Reconstr Surg* 81: 489, 1988
- Johnson CM Jr. and Toriumi DM. Open Structure Rhinoplasty. Philadelphia: Saunders, 1990. Additional information in Johnson CM, Wyatt CT. A Case Approach to Open Structure Rhinoplasty. 2nd ed. New York: Elsevier, 2006
- Meyer R Secondary Rhinoplasty. Berlin: Springer, 2002
- Sheen JH. Rhinoplasty: Personal evolution and milestones. *Plast Reconstr Surg* 105: 1820, 2000
- Sheen JH, and Sheen AP. Aesthetic Rhinoplasty (2nd ed.) St. Louis: Mosby, 1987
- Tardy ME. Rhinoplasty: The Art and the Science. Philadelphia: Saunders, 1997
- Tebbetts JB. Rethinking the logic and techniques of primary tip rhinoplasty. *Clin Plast Surg* 23: 245, 1996. (Entire Issue)
- Toriumi DM and Johnson CM. Open structure rhinoplasty: Featured technical points and long-term follow-up. *Facial Plast Clin* 1: 1, 1993. (Entire Issue)
- Toriumi, DM. New concepts in nasal tip contouring. *Arch Facial Plast Surg* 8: 156, 2006
- Thomas JR. The relationship of lateral osteotomies in rhinoplasty to the lacrimal drainage system. *Otolaryngology* 94: 362, 1986



<http://www.springer.com/978-3-642-01401-7>

Mastering Rhinoplasty
A Comprehensive Atlas of Surgical Techniques with
Integrated Video Clips

Daniel, R.K.

2010, XI, 449 p. With DVD., Hardcover

ISBN: 978-3-642-01401-7