HDTV ir NBI endoskopijos panaudojimas viršutinių kvėpavimo takų auglių diagnostikoje

Darius Rauba

UNIVERSITÀ DEGLI STUDI DI BRESCIA

UNIVERSITÀ DEGLI STUDI DI GENOVA

High Definition Television and Narrow Band Imaging endoscopy in the management of the UADT tumors

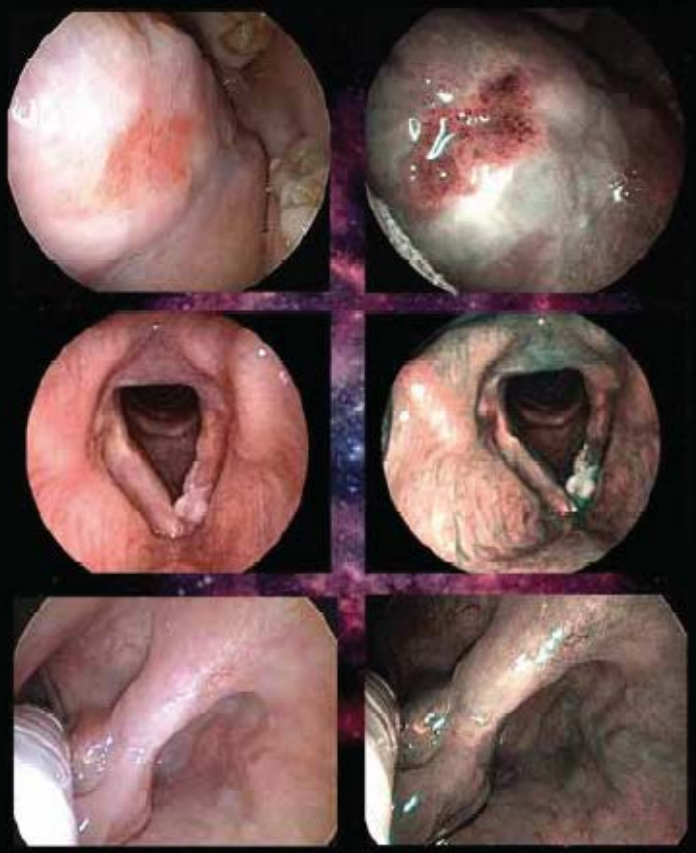

Brescia - Italy, October 17th/18th/19th 2012

Spedali Civili di Brescia, P.zza Spedali Civili 1, 25123 Brescia

The International Federation of Head and Neck Oncologic Societies

presents

Current Concepts in Head & Neck Surgery and Oncology

Piero Nicolai ▪ Brian O'Sullivan ▪ Jatin Shah ▪ Lisa Licitra ▪ Ashok Shaha ▪ Alexander Rapidis ▪ Daniel Fliss

Piero Nicolai

October 1 - 31, 2012

Global Continuing Education Program

www.ifhnosworldtour2012.org

Tour Schedule

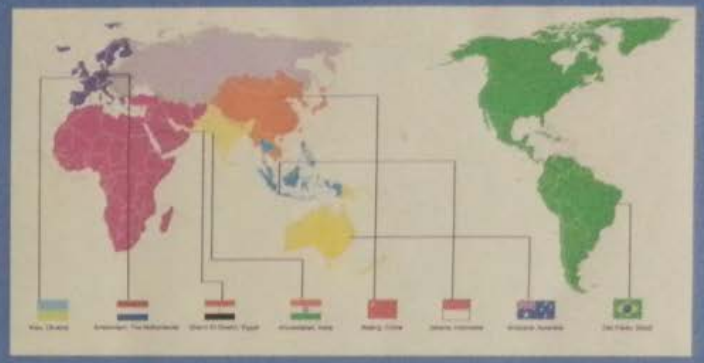

Region	Date	Location	Conference Coordinators
	Oct 1, 2 & 3, 2012	Kiev, Ukraine	Dr. Somasundaram Subramanian Dr. Igor Reshetov
	Oct 4, 5 & 6, 2012	Amsterdam, The Netherlands	Dr. Michiel van den Brekel
	Oct 8, 9 & 10, 2012	Sharm El Sheikh, Egypt	Dr. Hesham Negm and Dr. Ossama A. Hamid
	Oct 12, 13 & 14, 2012	Ahmedabad, India	Dr. Rajendra Toprani
	Oct 16, 17 & 18, 2012	Beijing, China	Dr. Zhenkun Yu
	Oct 20, 21 & 22, 2012	Jakarta, Indonesia	Dr. Marlinda Adham
	Oct 24, 25 & 26, 2012	Brisbane, Australia	Dr. Ben Wallwork
	Oct 28, 29 & 30, 2012	Sao Paulo, Brazil	Dr. Claudio Cernea

Prof. Giorgio Peretti g.1958m

Europos laringologų draugijos “president elect”

SHAPSHAY-PERETTI Micro Grasping Forceps,
curved upwards to left, serrated, with triangular fenestrated jaws, with cleaning connector, working length 20 cm

PERETTI High Pressure Syringe,
for fat injection

Spedali Civili di Brescia
Università degli Studi di Brescia
U.O.OTORINOLARINGOIATRIA
DIREZIONE - SEGRETERIA - AULA
Direttore:
Prof. PIERO NICOLAI
Scala
Ala Ovest
REPARTI
Urologia Femminile
2a Chirurgia Femminile
Day ospital Ematologia
Day Hospital Oncologia
Chirurgia
Pediatrica
U.O. Riabilitazione
1a Divisione Ortopedia e Traun atologia
Policardiografia
Allergologia
1a Rianimazione
Bar - Emporio
Medicina Preventiva
Uffici Tecnici
Ufficio Dietetico

ULTRA Pulse
Ready
Standby
Scan
3.0W
21ms
0.00s
LUMENIS
ULTRA pulse

SurgiTouch
UltraPulse
CW
Options
ULTRA Pulse
Ready
Standby
ENT
Larynx
350mm
Acublade
Nonscan
Scan
Shape: 4
Size: 0.9 mm
Depth: 1
Power
2.5W
10.0 W
Off
21ms
Repeat Delay
On
0.00s
Memory
LUMENIS
ULTRA pulse

NBI diagnostikos principas

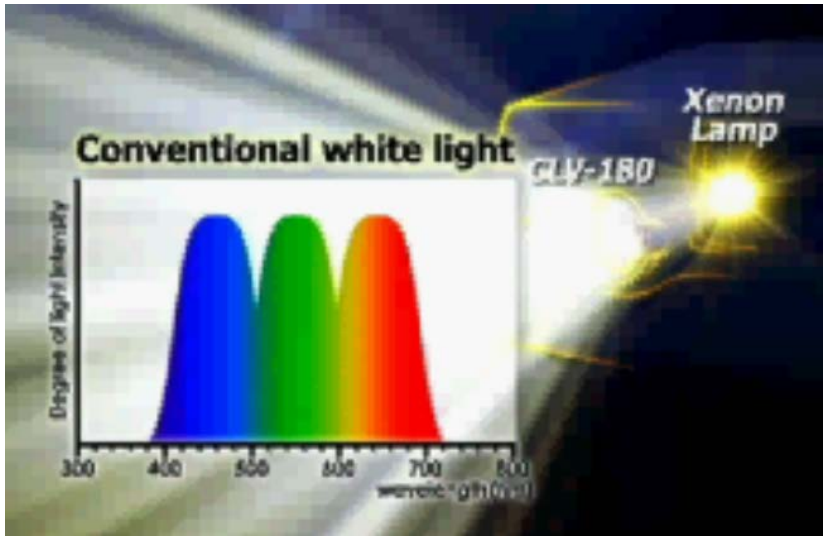

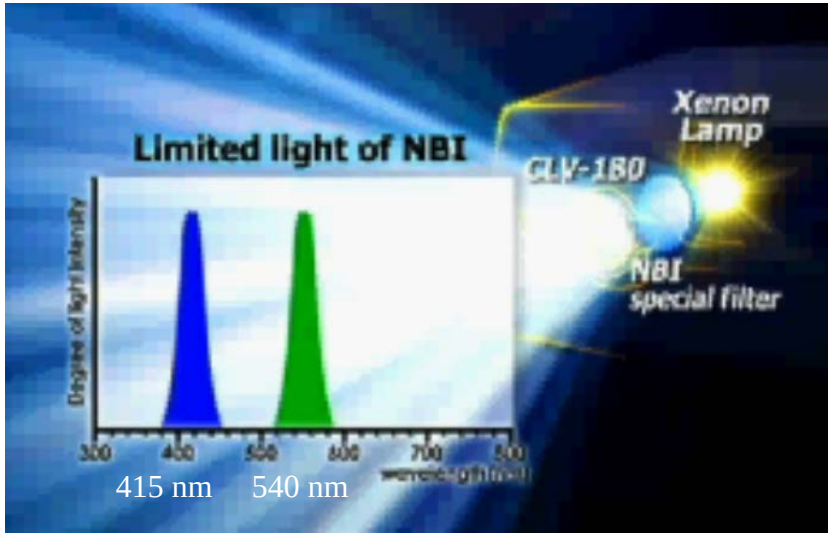

NBI diagnostikos principas

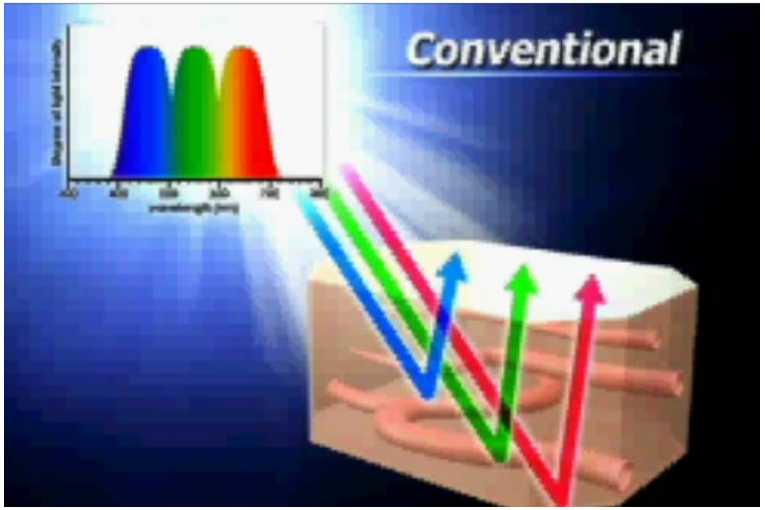

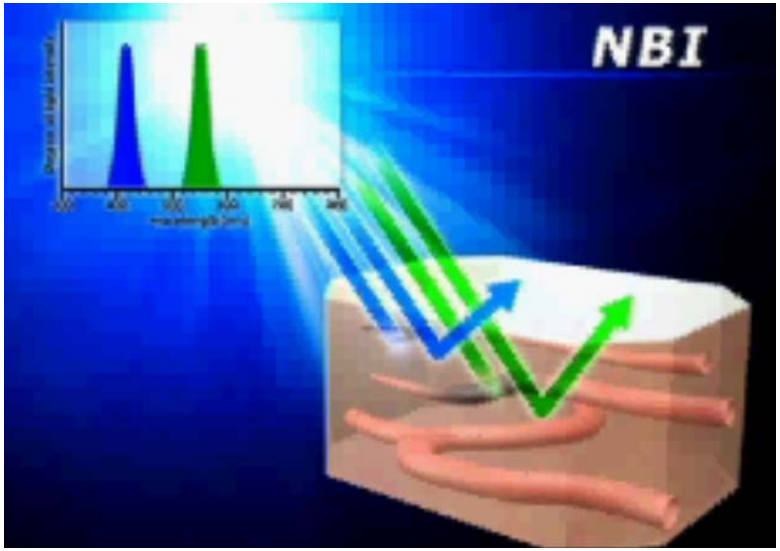

Filtruota šviesa nepraeina giliau paviršinio gleivinės sluoksnio

Mėlyną spalvą geriausiai sugeria hemoglobinas, todėl kraujagyslės, sugerdamos 415nm mėlyną šviesą atrodo tamsesnės nei aplinkinė gleivinė, kuri atspindi šviesą

Kapiliarai gleivinės paviršiuje matosi rudos spalvos, o didesnės ir gilesnės venos – violetinės spalvos.

NBI diagnostikos principas

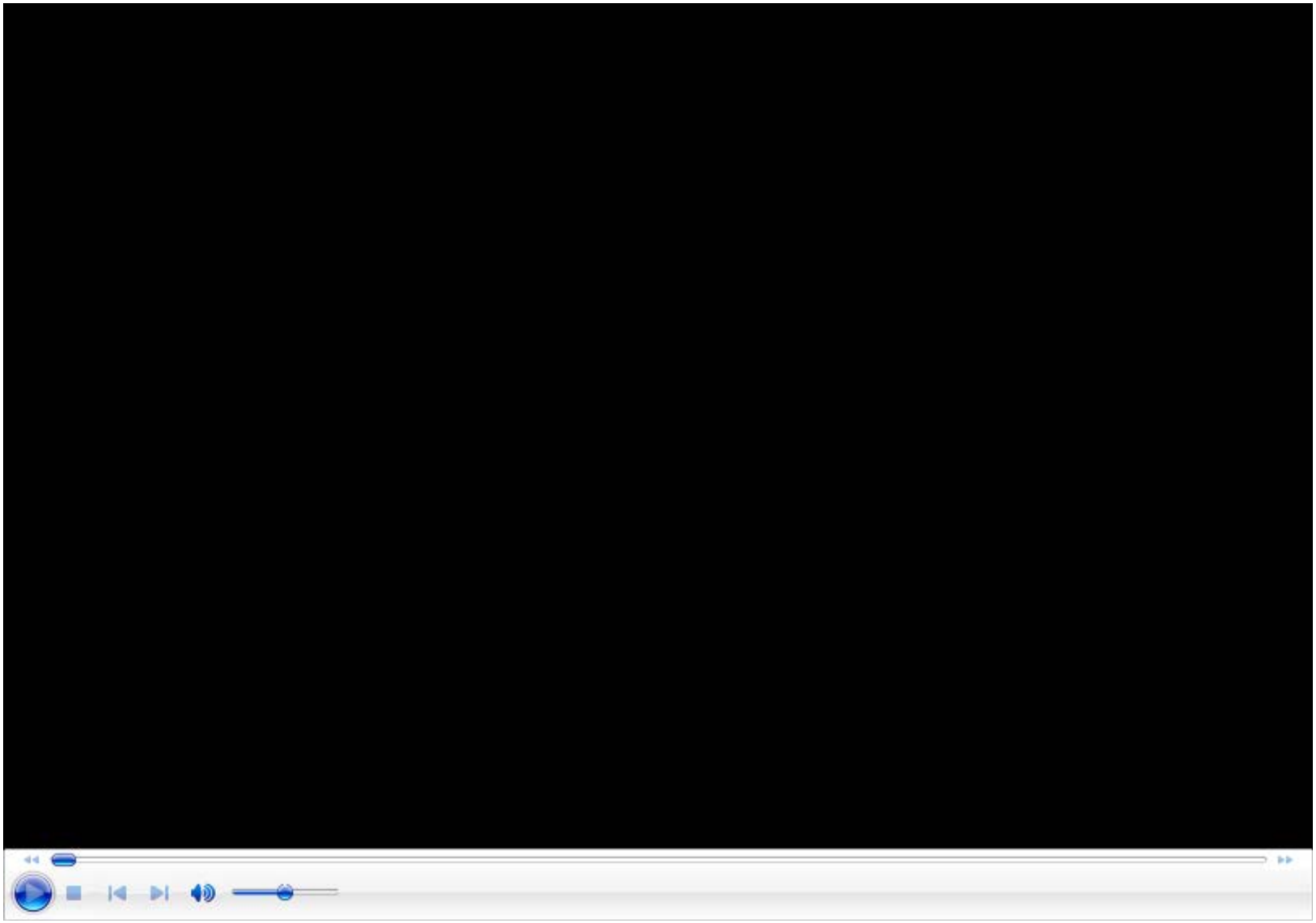

NBI panaudojimas

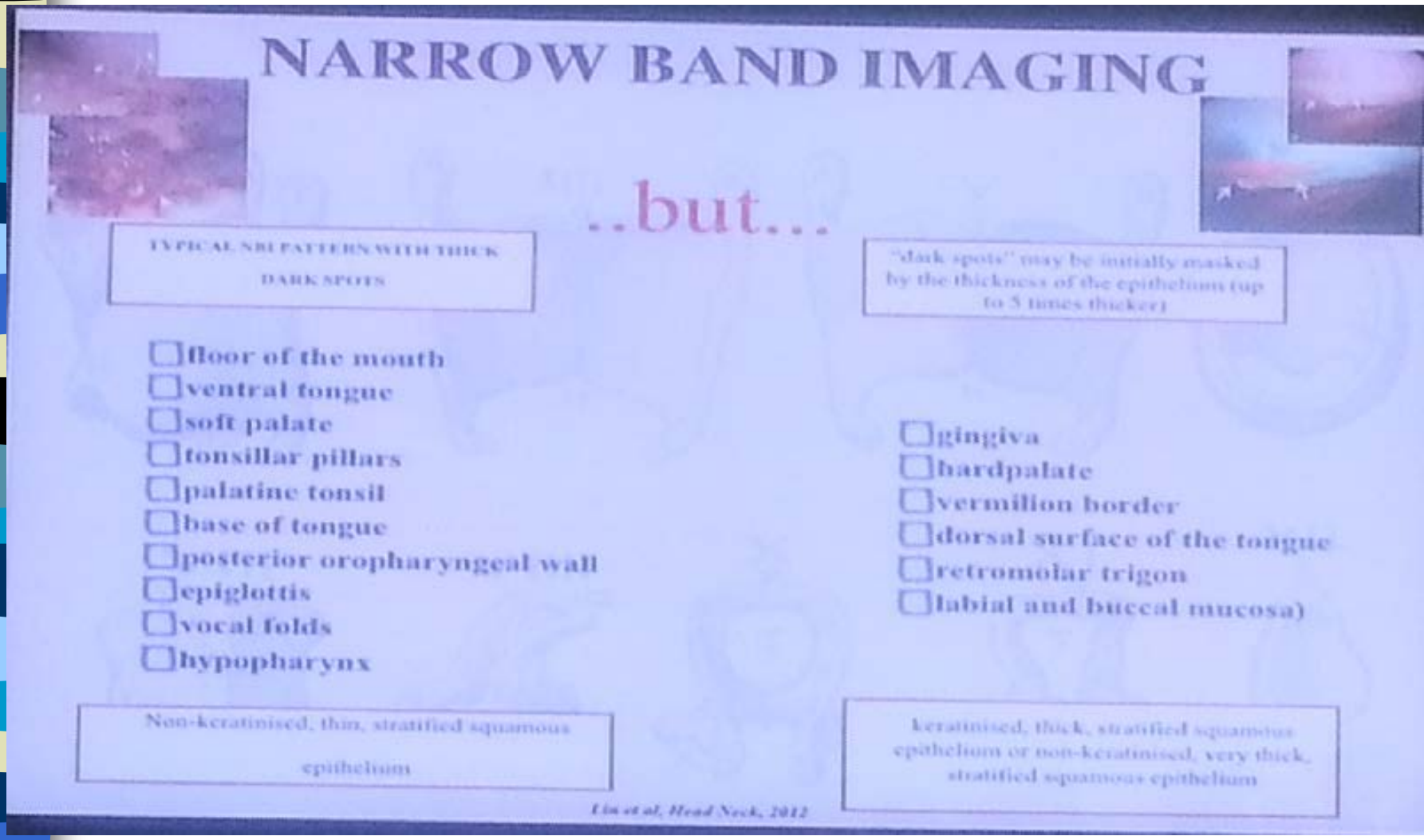

NBI panaudojimas

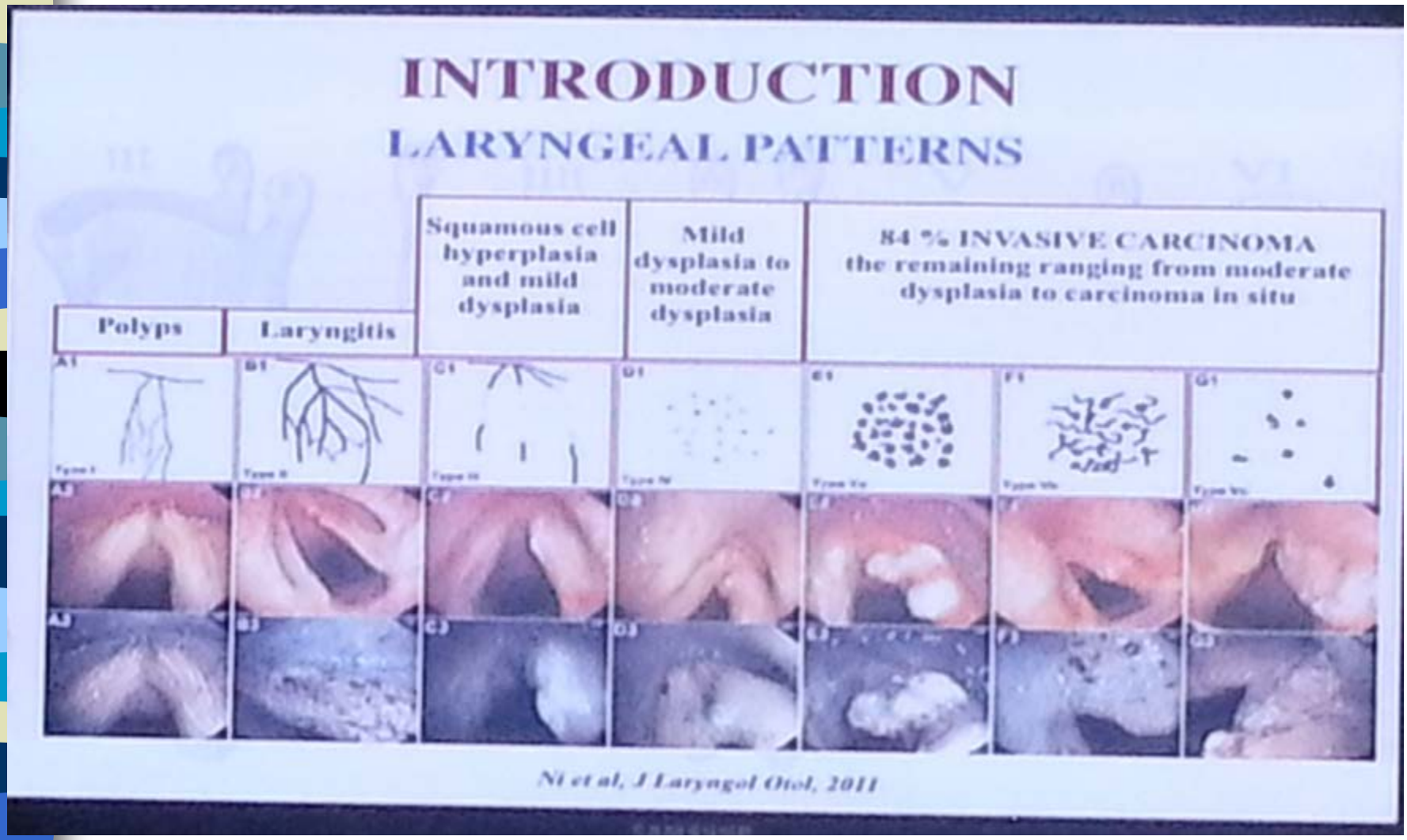

Ca in situ

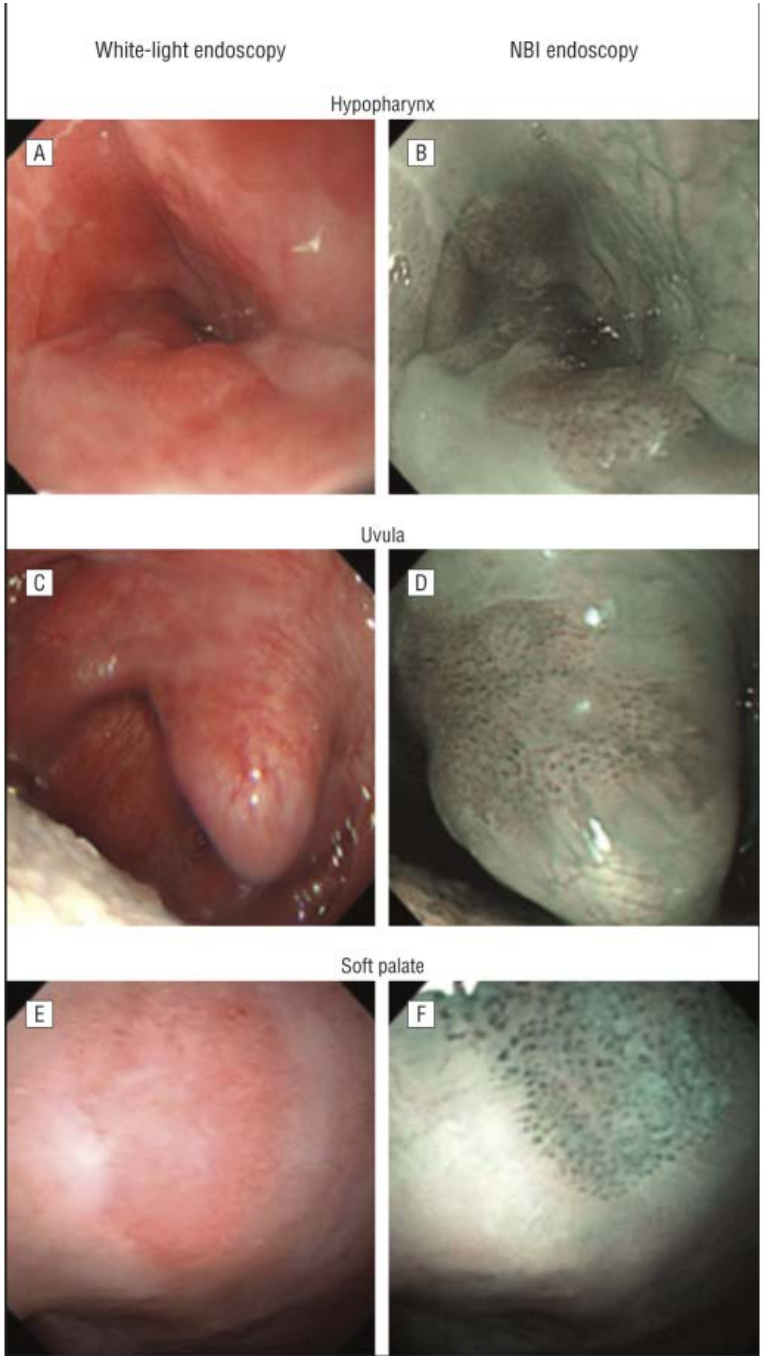
White-light endoscopy
NBI endoscopy
Hypopharynx
A
B
Uvula
C
D
Soft palate
E
F

Klinikinis atvejas. Priešoperacinis ištyrimas

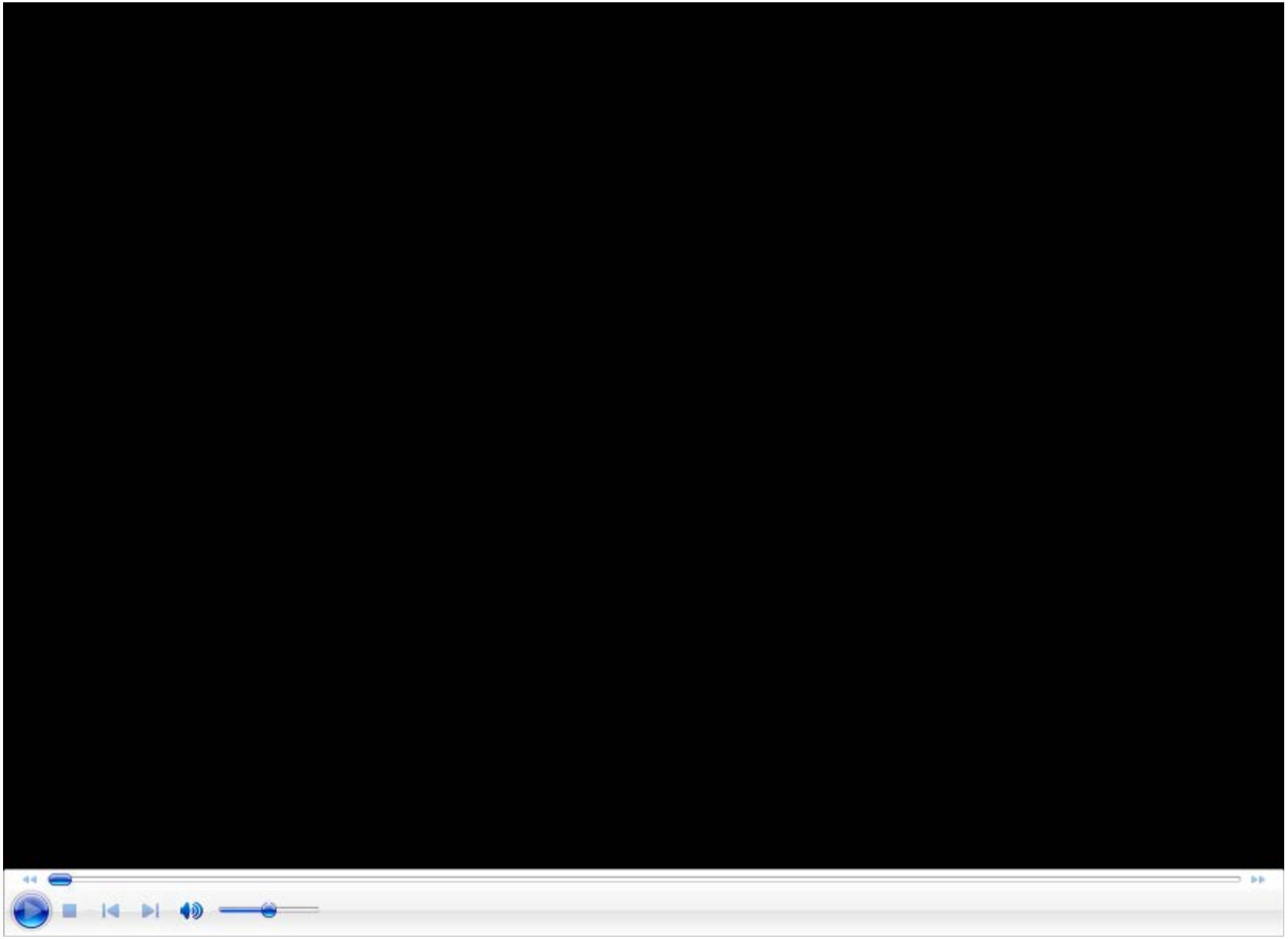

Klinikinis atvejas. Apžiūra endoskopais operacinėje

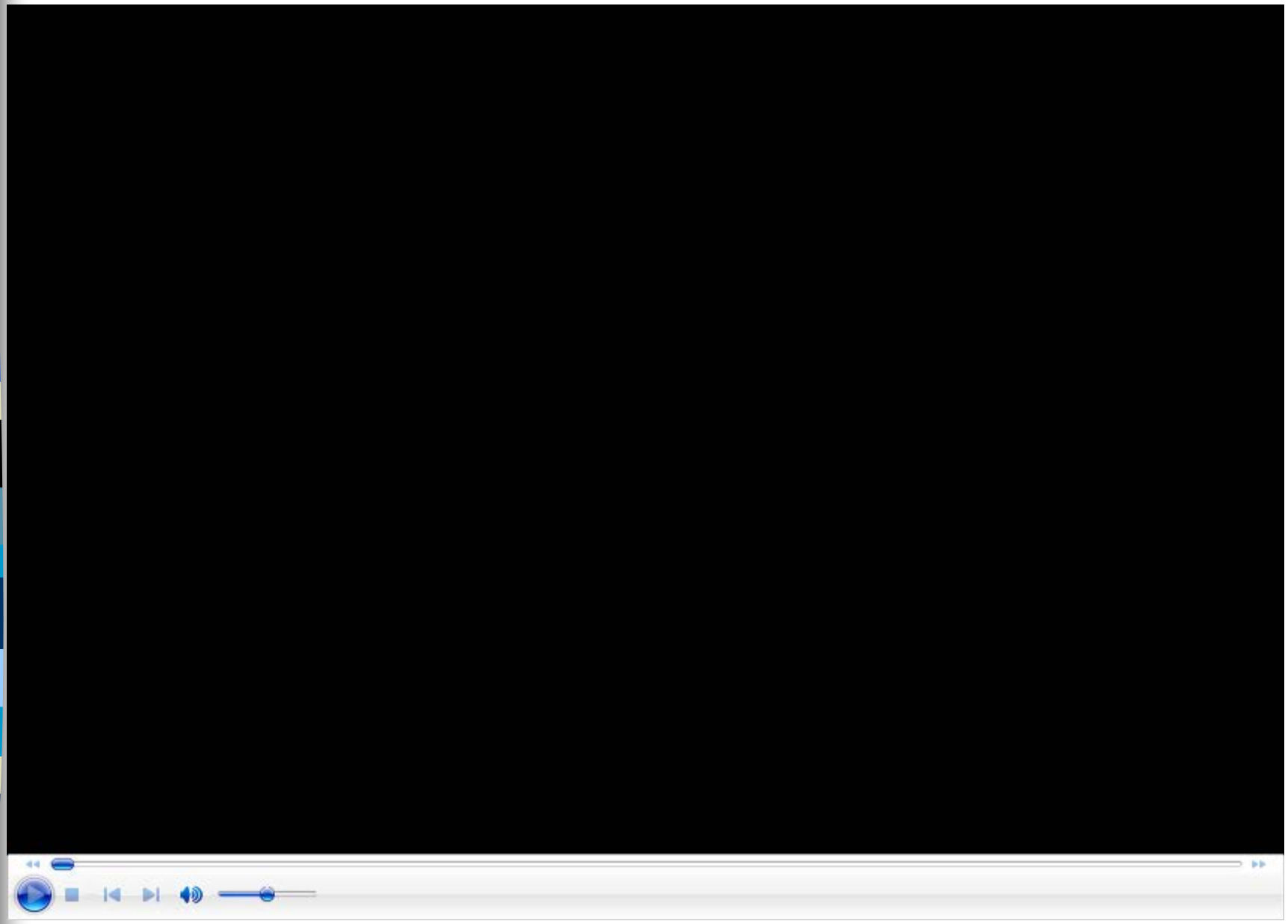

Klinikinis atvejas. Ribų pažymėjimas

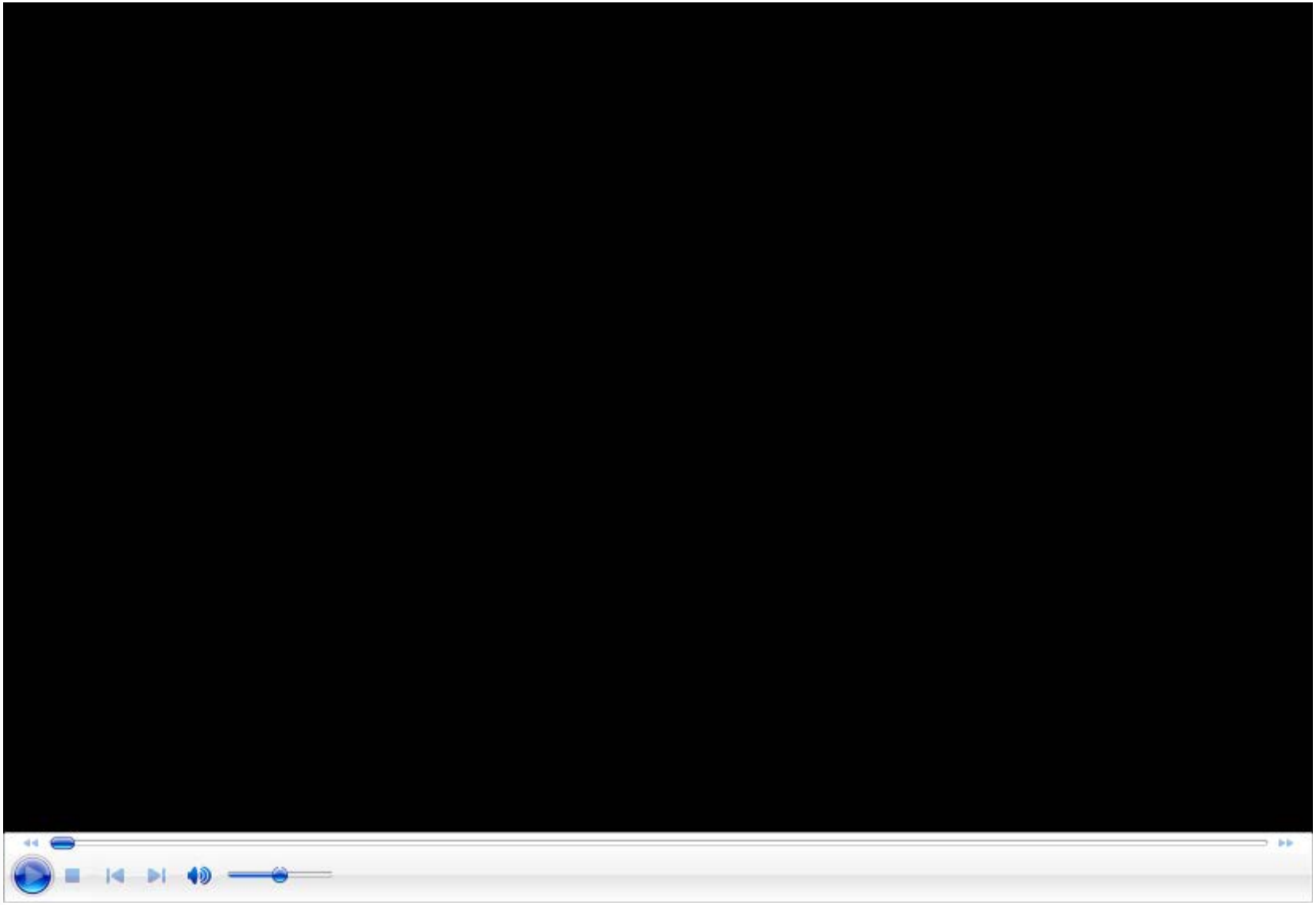

Klinikinis atvejas. Ribų pažymėjimas

Arch Otolaryngol Head Neck Surg. 2010;136(3):234-239.
Original Article| March 15, 2010

Narrowband Imaging for Early Detection of Malignant Tumors and Radiation Effect After Treatment of Head and Neck Cancer

Table 3. Comparison of the Detection Rates of Standard Endoscopy and NBI Depending on the Cancer Stage (62 Cancerous Foci in 39 Patients)

Cancer Stage	No. of Patients	No. (%) of Foci Detected		*P* Value[a]
		Conventional Endoscopy	NBI	
Visible cancers (T1-T4)	49	49 (100)	48 (98)	7.99
Carcinoma in situ (T0)	13	0	13 (100)	<.001
Total No. of Foci	**62**	**49** (79)	**61** (98)	NA

Abbreviations: NA, not applicable; NBI, narrowband imaging.
[a] Fisher exact test.

Išvados:

No difference was found between the 2 modes with regard to the detection of visible T1 to T4 tumors. However, NBI mode was significantly superior to white-light mode for the detection of precancerous lesions in the oropharyngeal and hypopharyngeal mucosa

The diagnostic accuracy of endoscopy performed in white-light and NBI modes was 100% and 97% for lesions in the oral cavity, 69% and 100% for those in the oropharynx *(P=.02), and 39% and 100%* for those in the hypopharynx (*P=.001), respectively*.